

Test Your Diagnostic Skills in Vulvar Diseases for a Variety of Fitzpatrick Skin Types



Importance of this clinical skill

- Women of color are historically underrepresented in dermatology and gynecology education. Limited educational tools contribute to the challenge of diagnosing vulvovaginal diseases and identifying the different appearances in various populations, particularly women of color.
- This results in highly variable approaches to management and sub-optimal therapeutic outcomes for Black and other dark-skinned women
- Very few textbooks or articles in the literature show vulvar diseases on dark skin

Fitzpatrick Skin Types

Type

- 1
- 2
- 3
- 4
- 5
- 6

Color

- Very white or freckled
- White
- White to olive
- Brown
- Dark brown
- Black

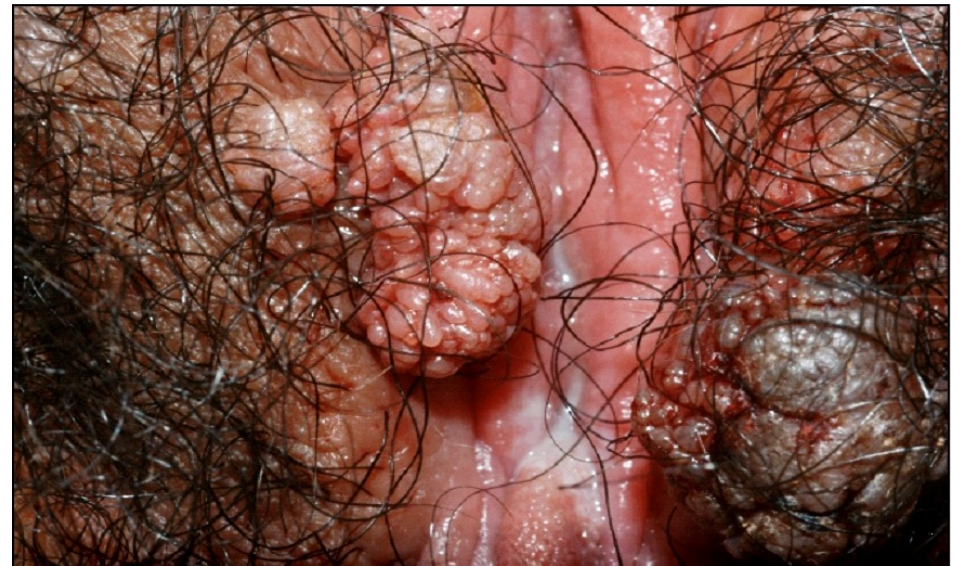Common Conditions

Case #1

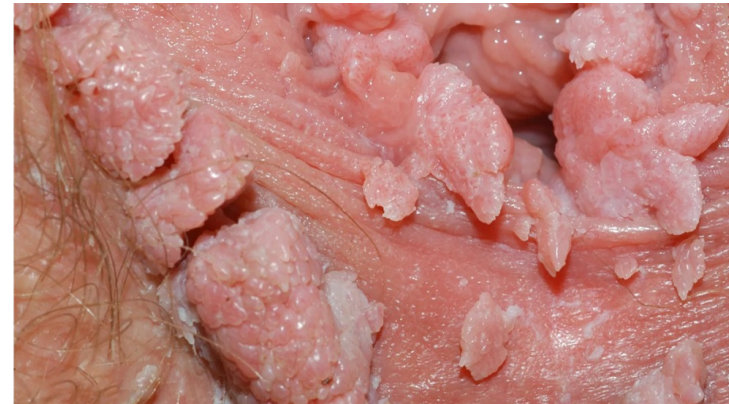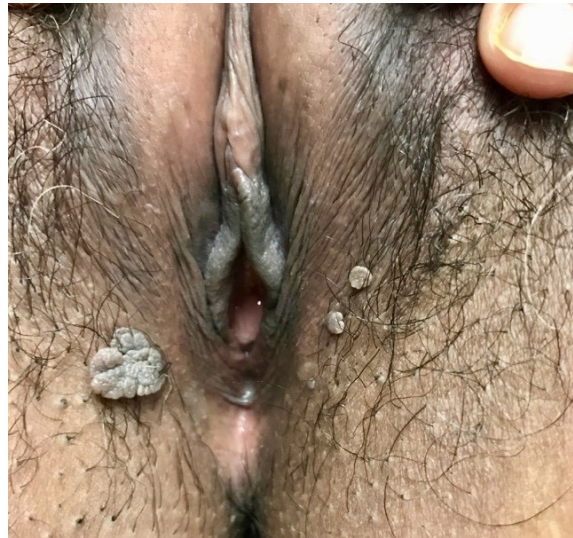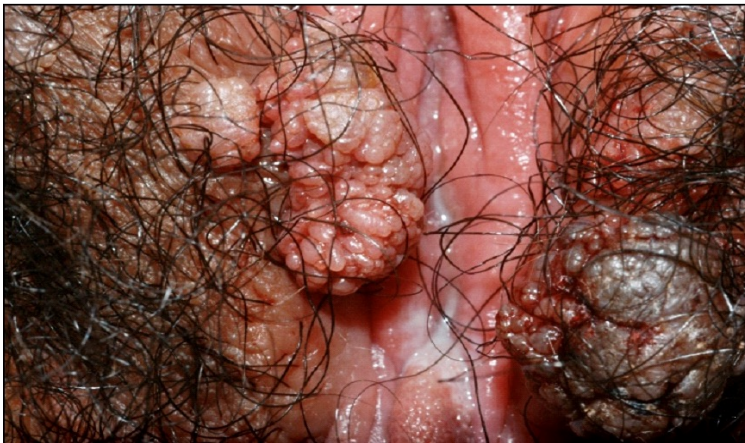22 y.o. female notices uncomfortable growths on her labia. When asked about HPV vaccinations, she isn't sure if she received them.

**Name this
vulvar condition**

- Low grade squamous intraepithelial lesion (LSIL) of the vulva (condylomata acuminata)
- Lichen simple chronicus
- Paget's disease
- Squamous cell carcinoma



LSIL of the vulva (condylomata acuminata)

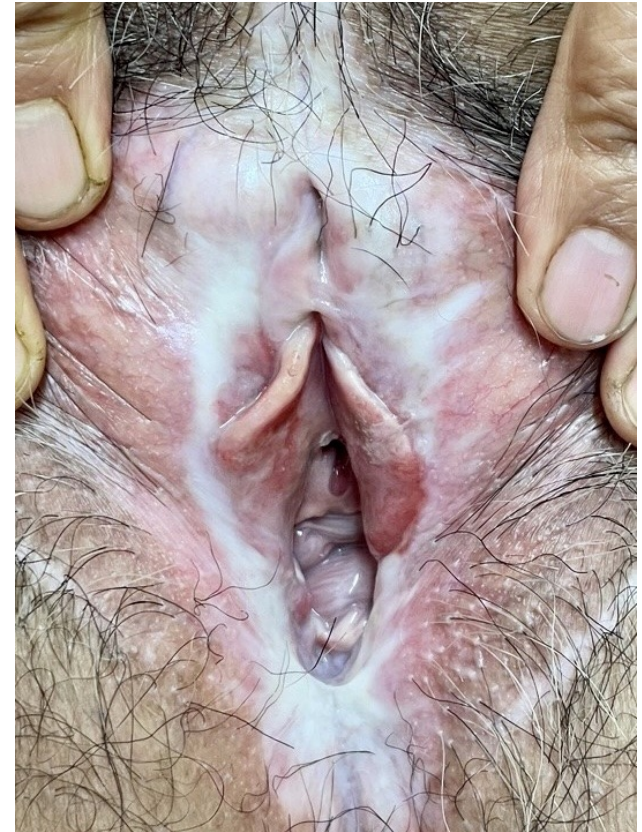

Case #2

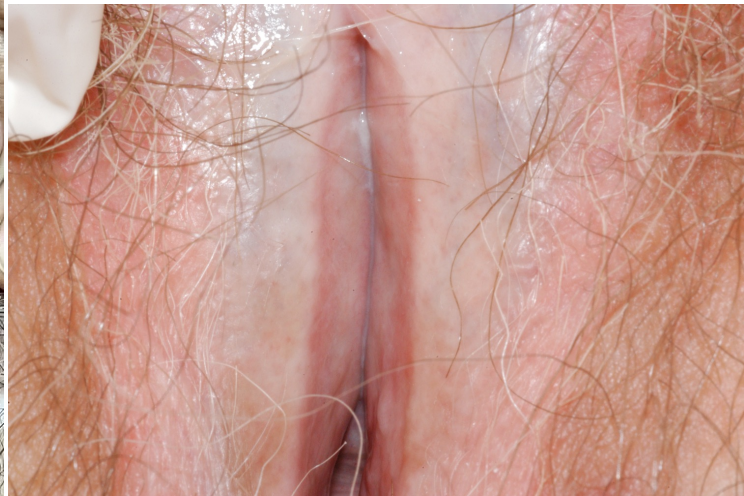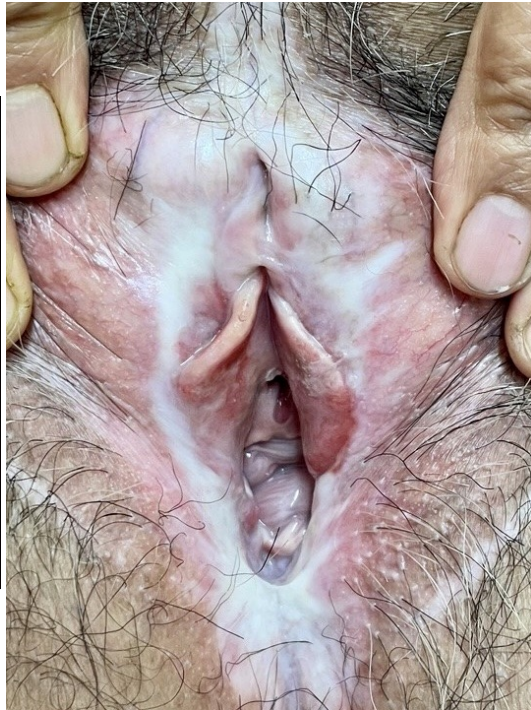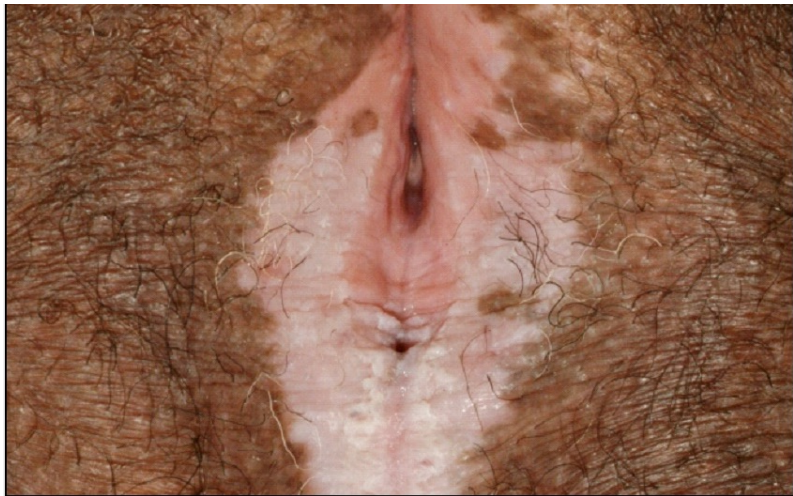
60 y.o. female mentions that she has uncomfortable groin itching and pain with intercourse. Her yeast culture is negative.

**Name this
vulvar condition**

- Post-menopausal atrophy
- Vulvar psoriasis
- Vulvar dermatitis
- Lichen sclerosus



Lichen sclerosus

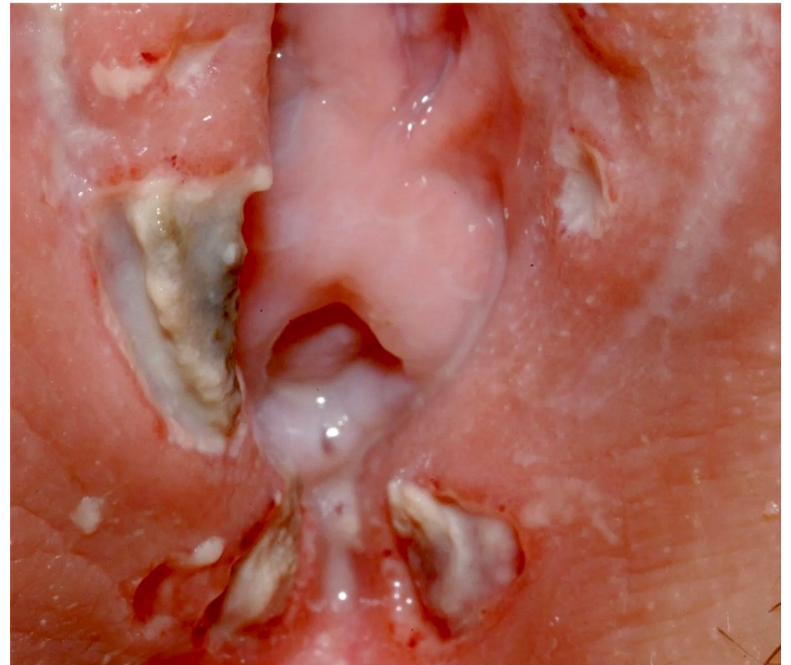

Case #3

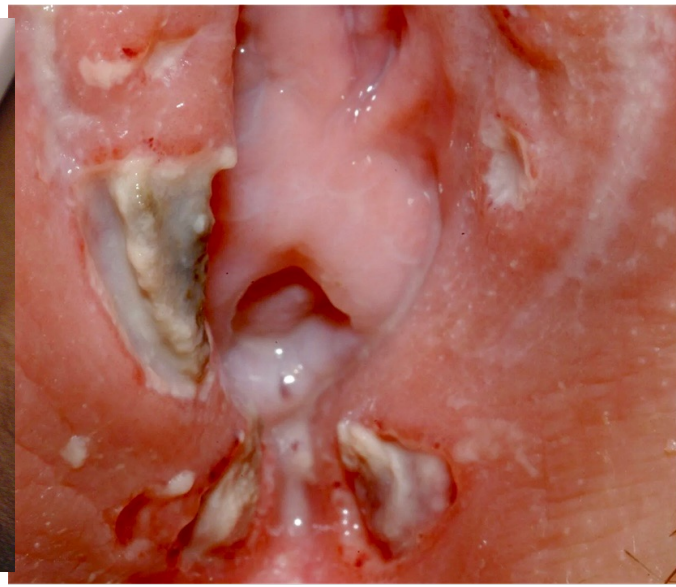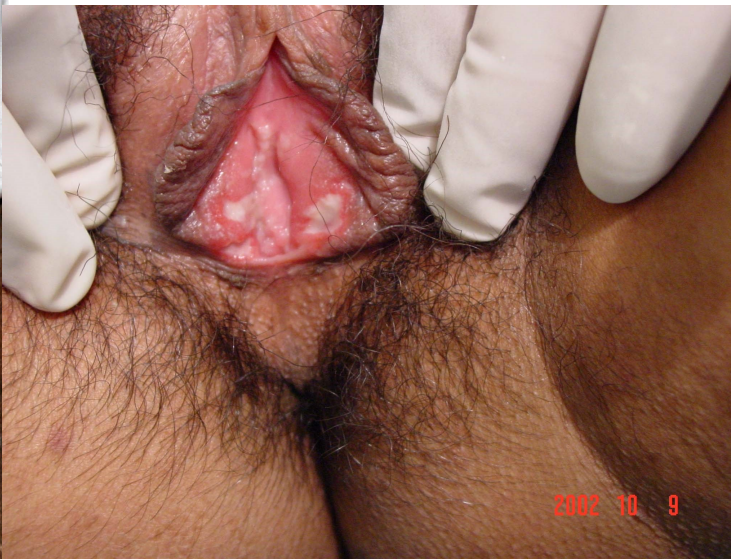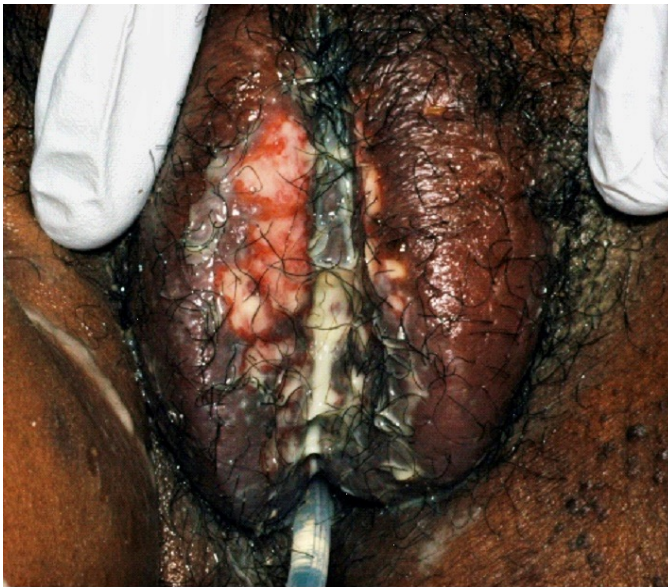34 y.o. female with recurring painful ulcers on her vulva

**Name this
vulvar condition**

- Herpes simplex virus
- Aphthous ulcers
- Behcet's disease
- Lichen planus



Aphthous ulcers

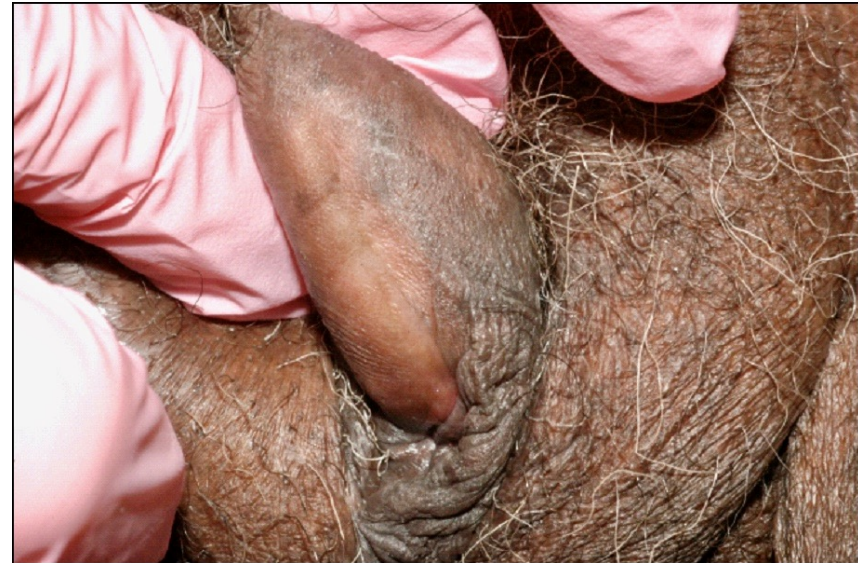

Case #4

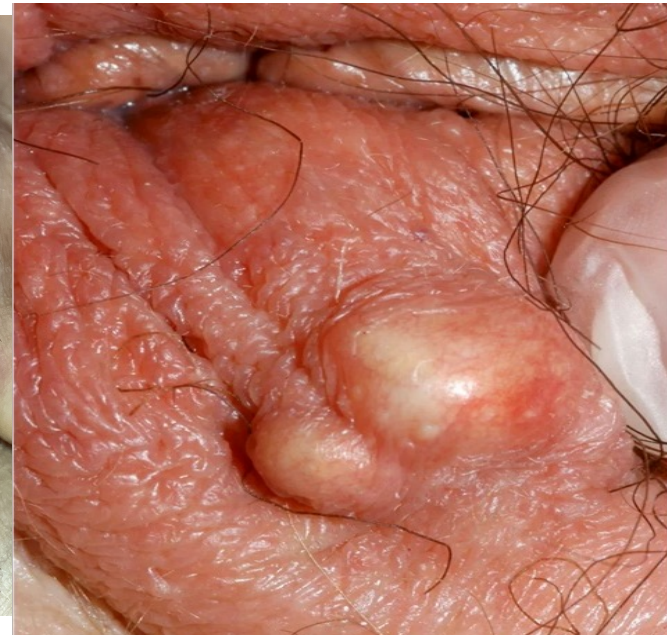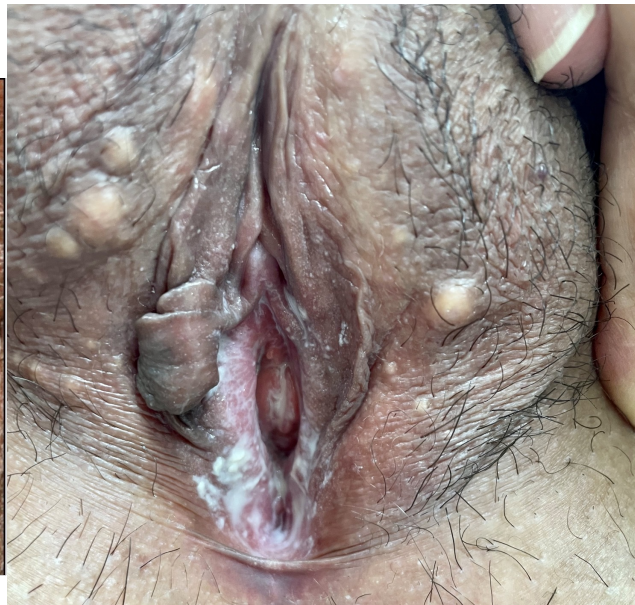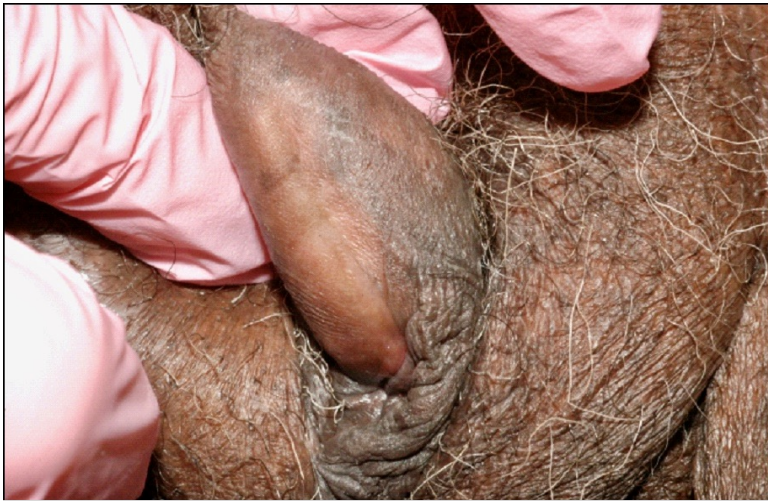45 y.o. female presents with small, painless bumps on her vulva

**Name this
vulvar condition**

- Epidermal inclusion cysts
- Bartholin's cysts
- Lipomas
- Vulvar abscesses



Epidermal inclusion cysts

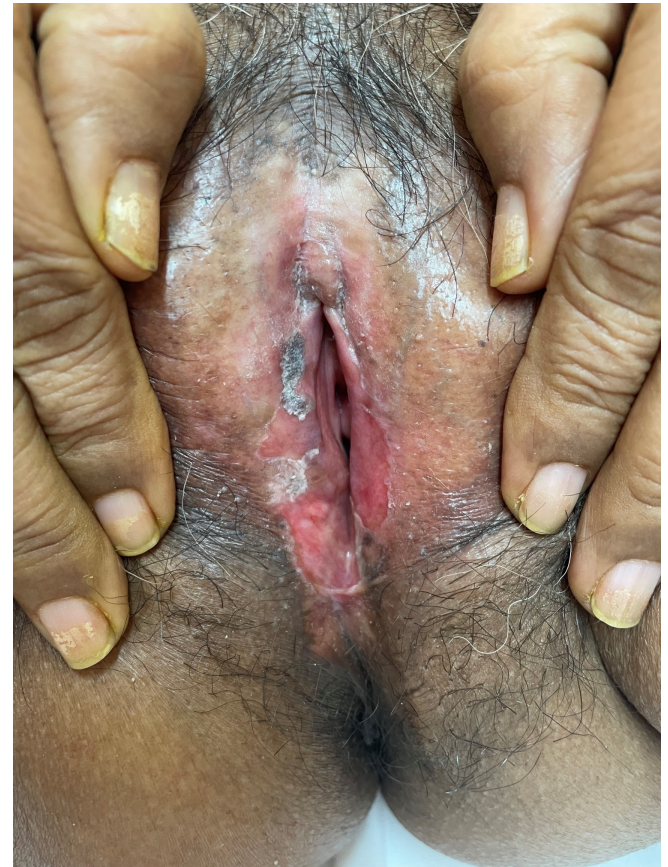

Case #5

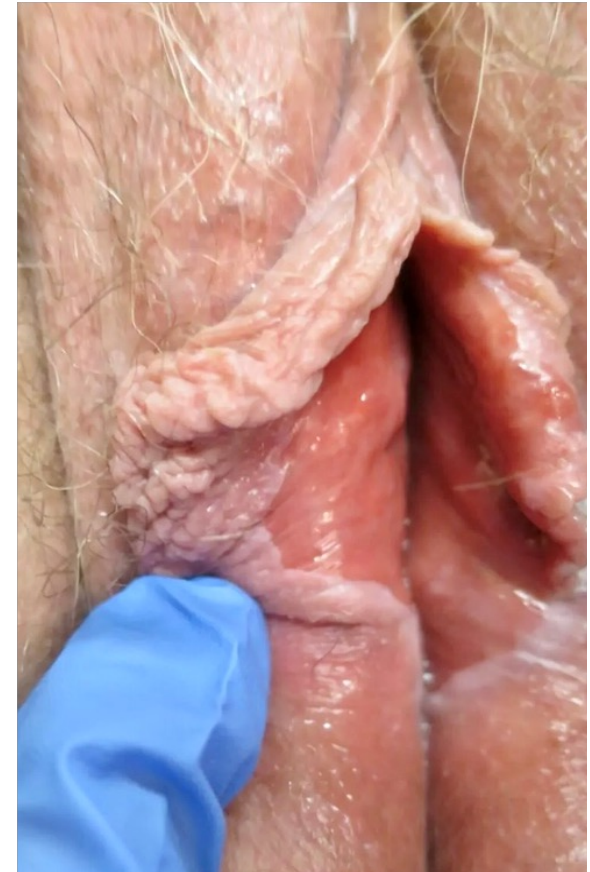
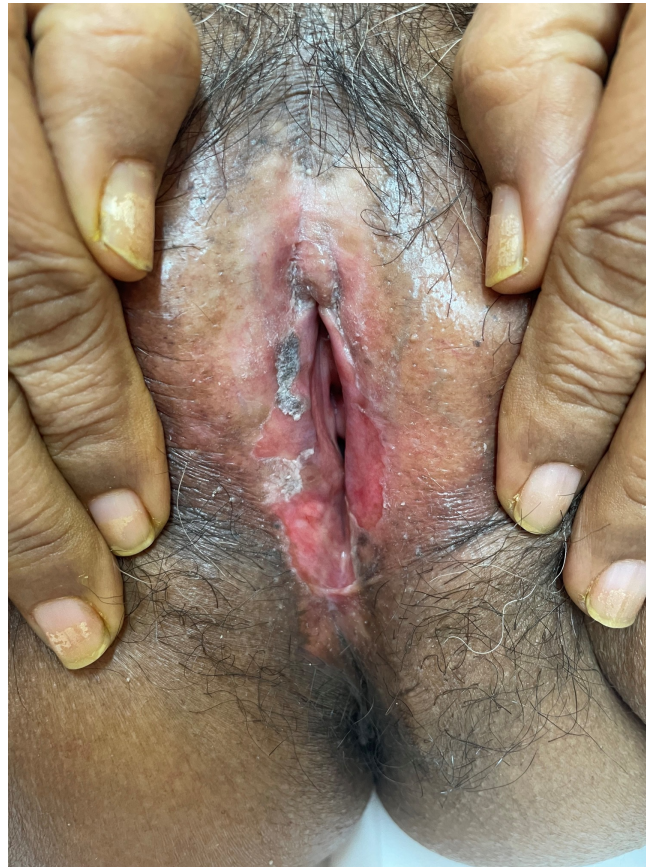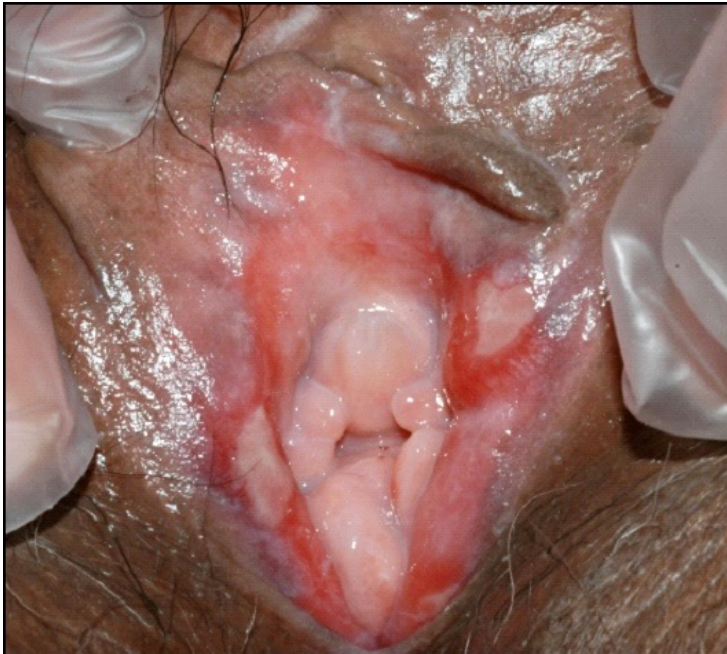50 y.o. female has persistent vulvar itching and painful lesions

**Name this
vulvar condition**

- Pemphigoid
- Lichen planus
- Eczema
- Herpes simplex virus



Lichen planus

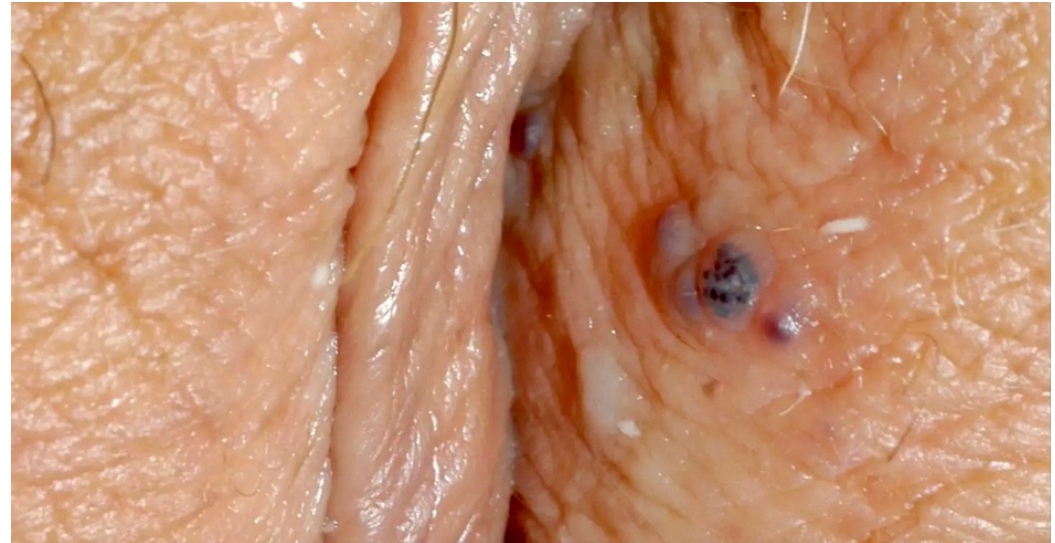

Case #6

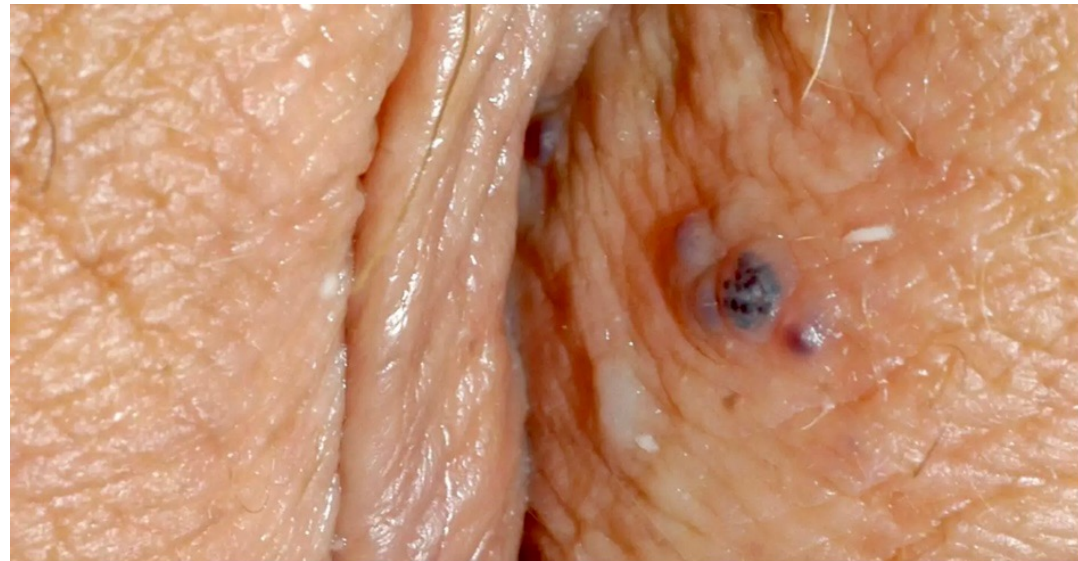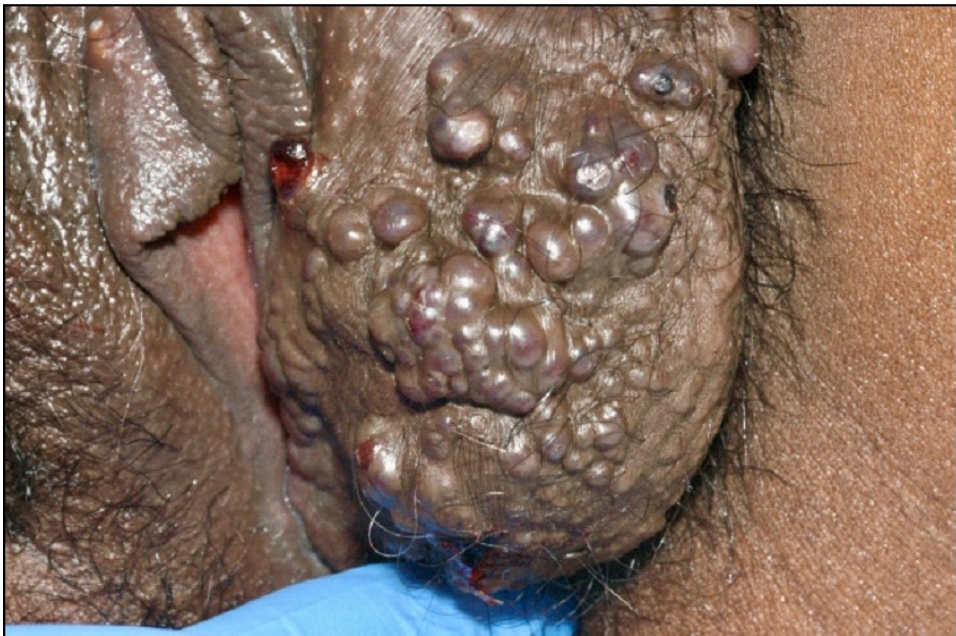38 y.o. female is noted to have discomfort, swelling, and pressure on her vulva

**Name this
vulvar condition**

- Hemangiomas
- Lymphadenopathy
- Bartholin's cysts
- Varicosities



Varicosities

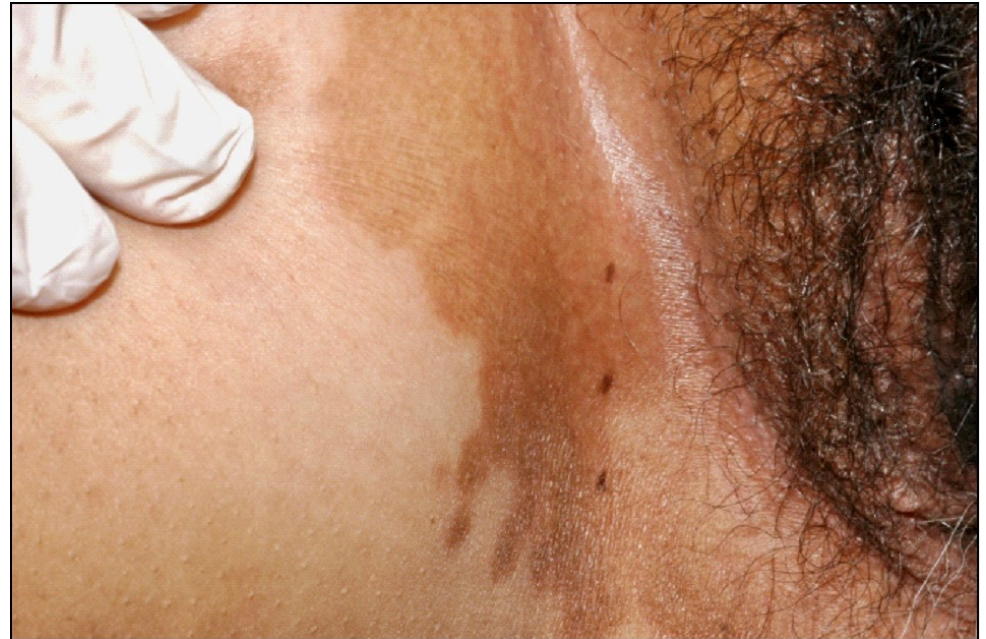

Case #7

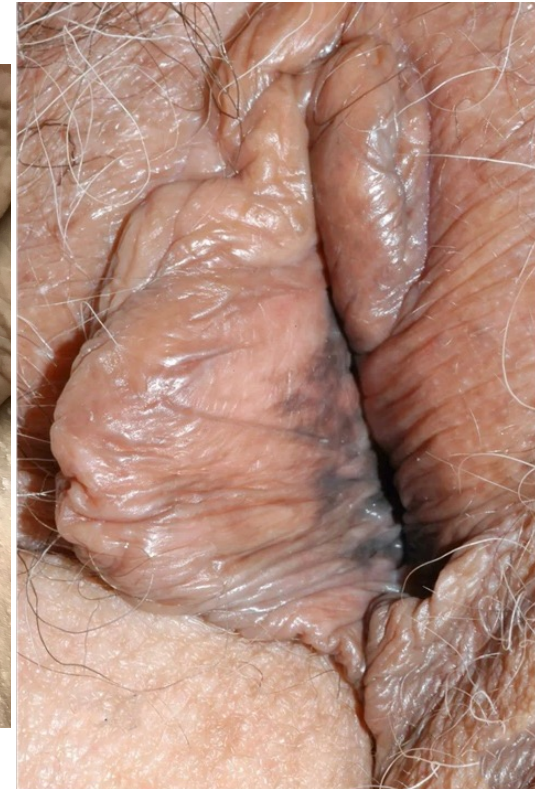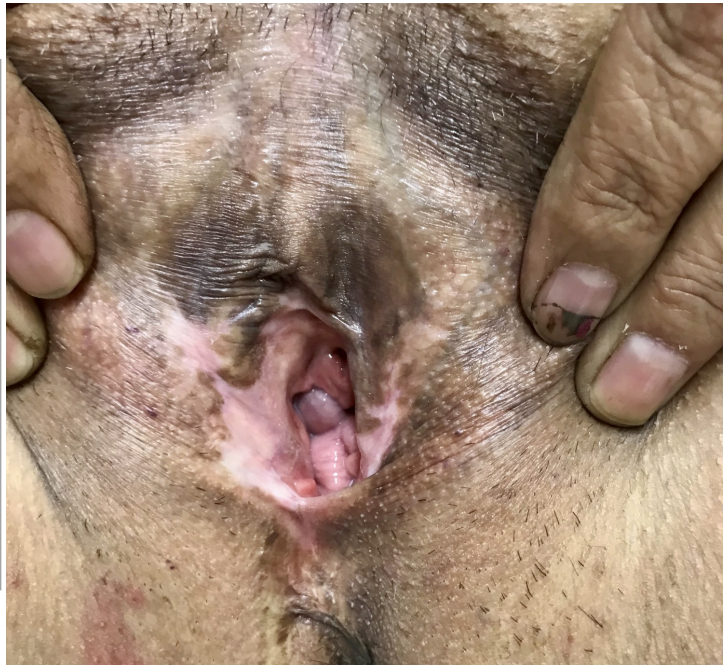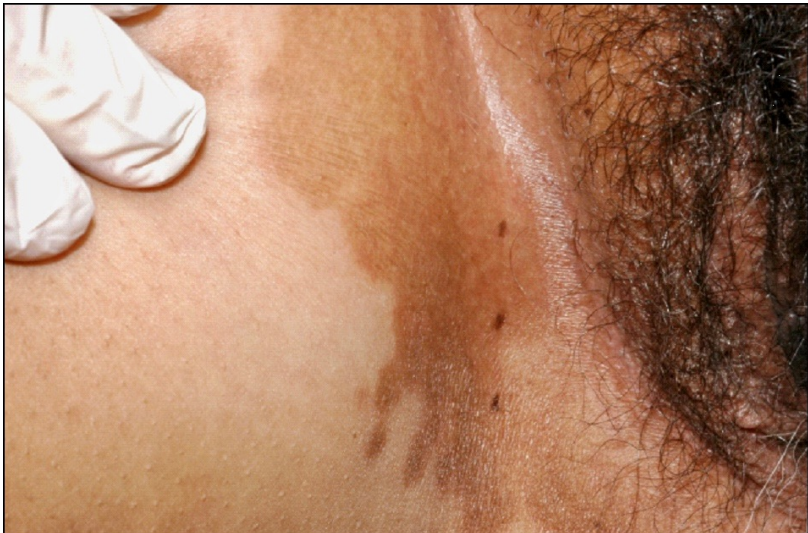29 y.o. female if found to have pigmented patches on her vulva

**Name this
vulvar condition**

- Melanosis
- Seborrheic keratosis
- Angiokeratomas
- Basal cell carcinoma



Melanosis

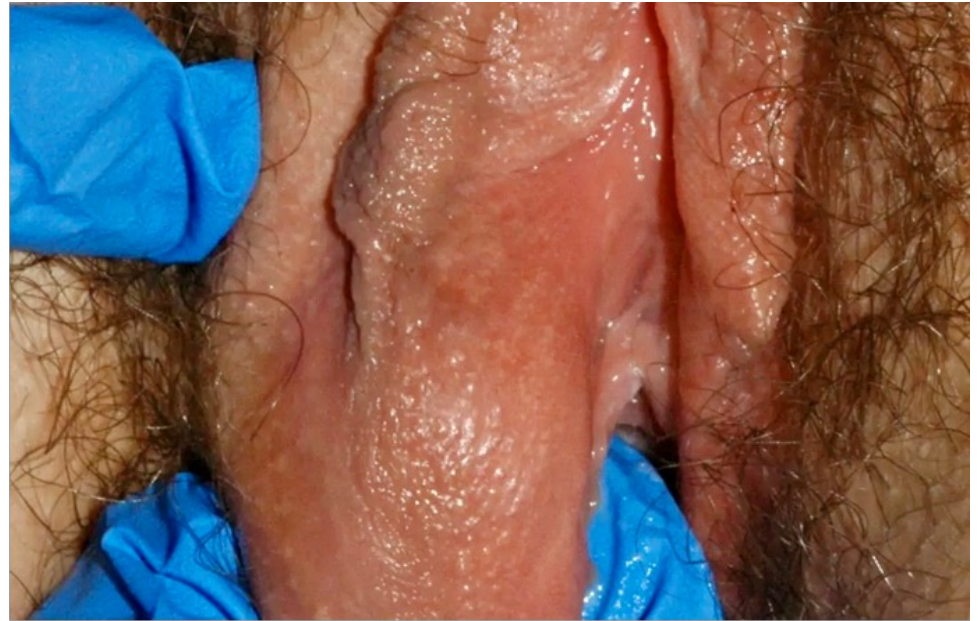

Case #8

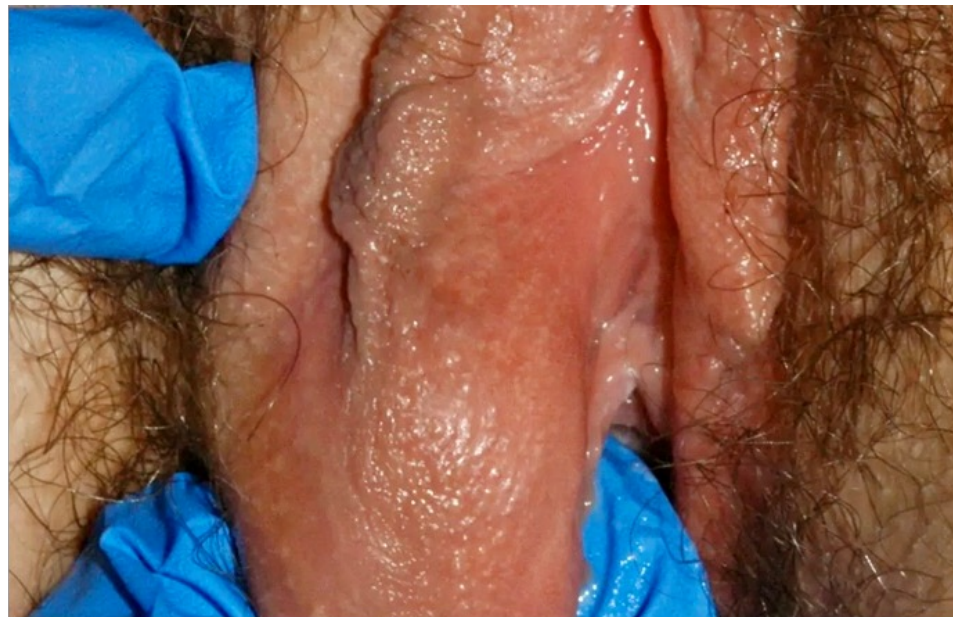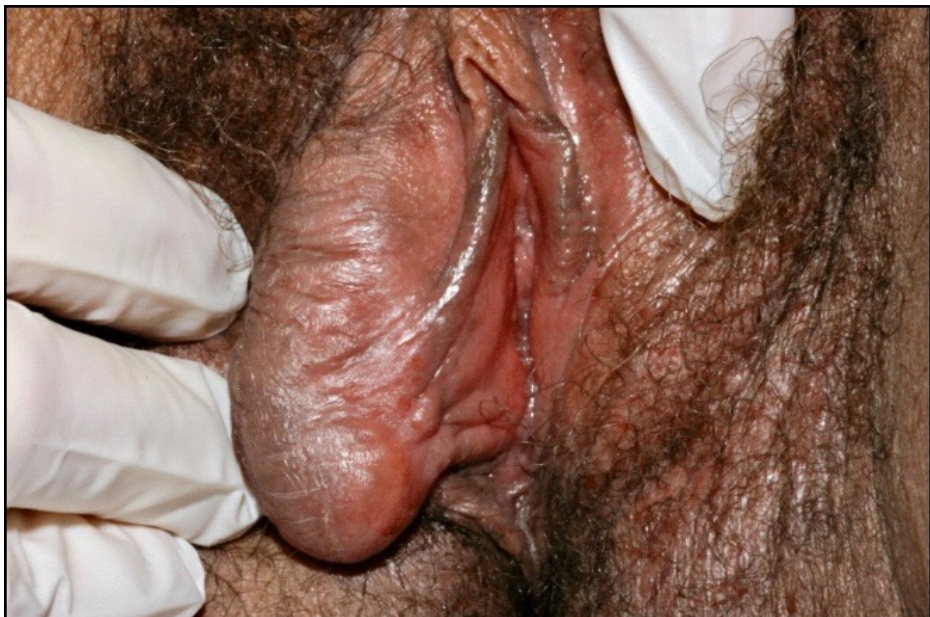36 y.o. female notices a painful swelling on her vulva

**Name this
vulvar condition**

- Lipoma
- Epidermal inclusion cyst
- Bartholin's cyst
- Lymphangioma



Bartholin's cyst

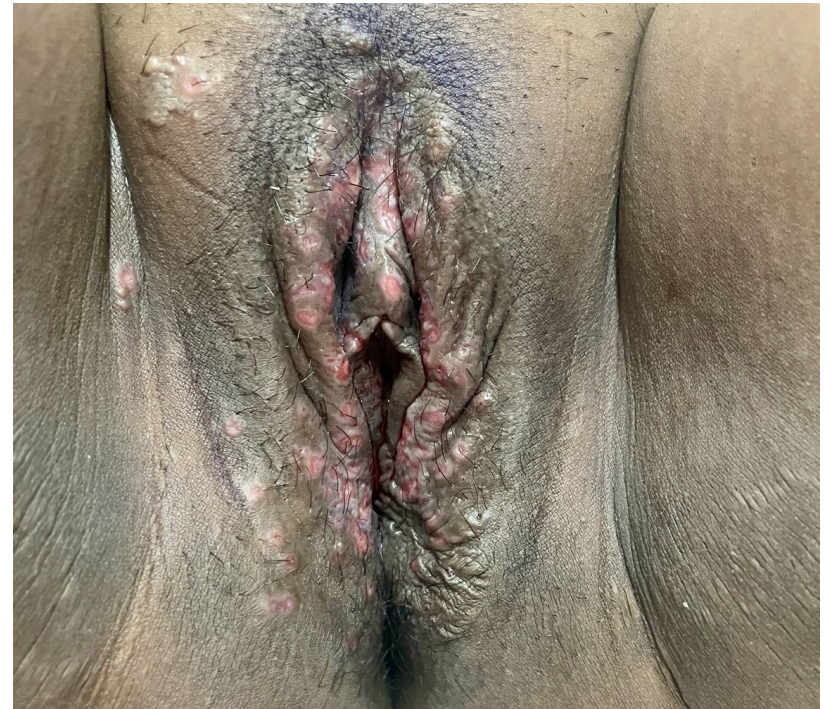

Case #9

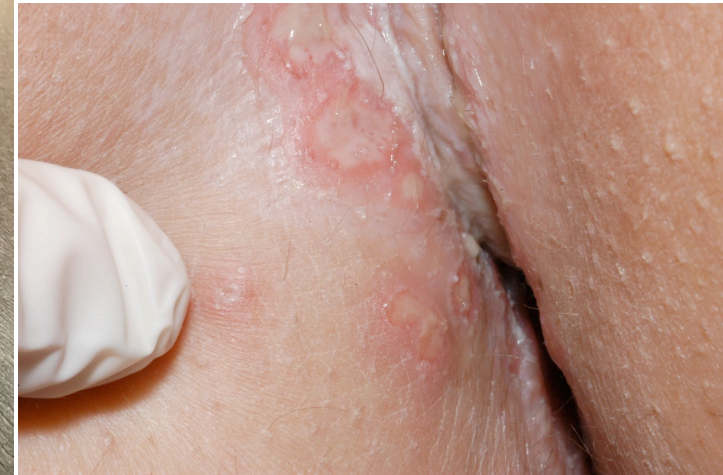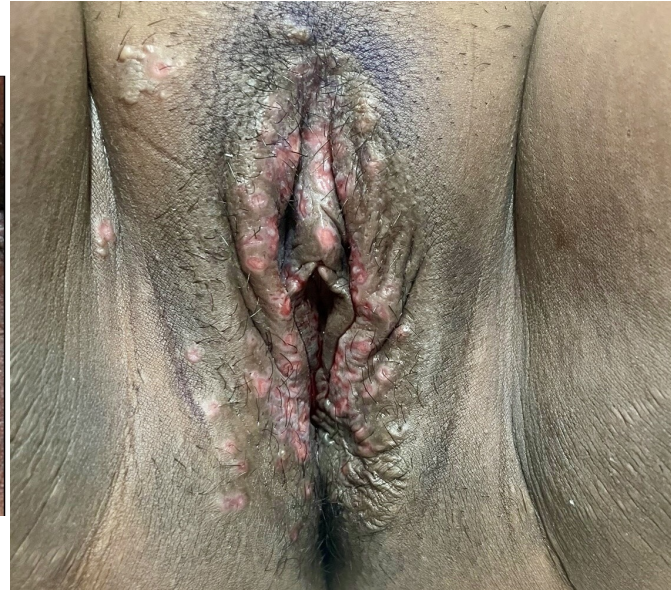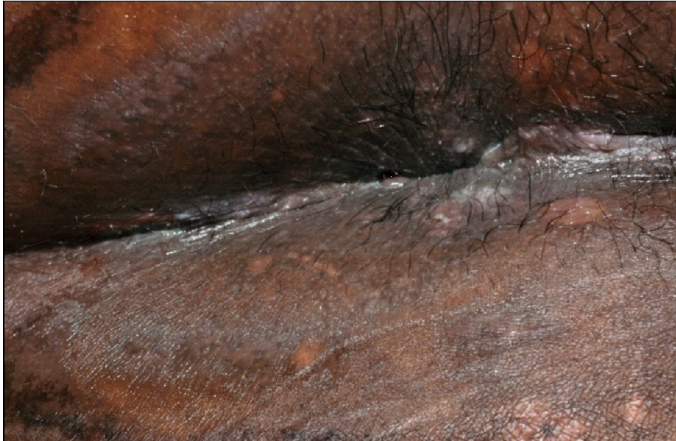27 y.o. female presents with recurrent, painful sores on her vulva

**Name this
vulvar condition**

- Herpes simplex virus
- Candidiasis
- Behcet's disease
- Paget's disease



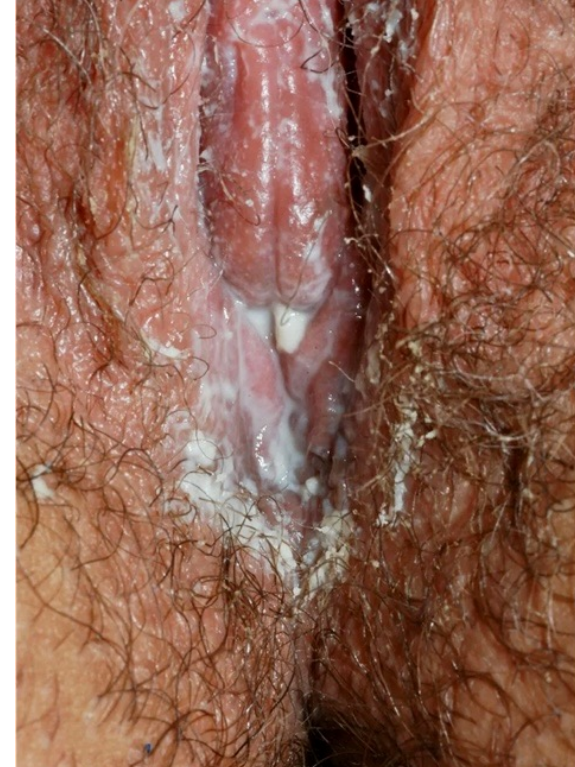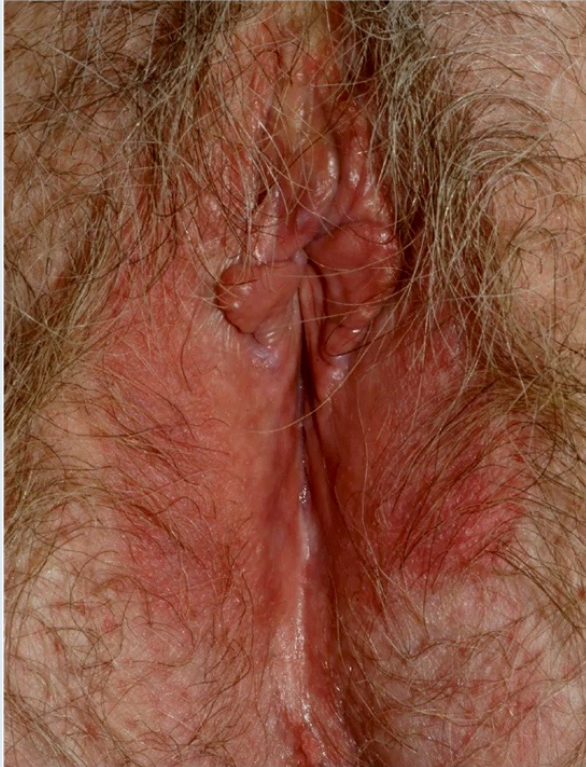
Herpes simplex virus



Case #10

Two women present with vulvar irritation. One complains of vulvar burning, and the other complains of thick white vaginal discharge and vulvar itching.

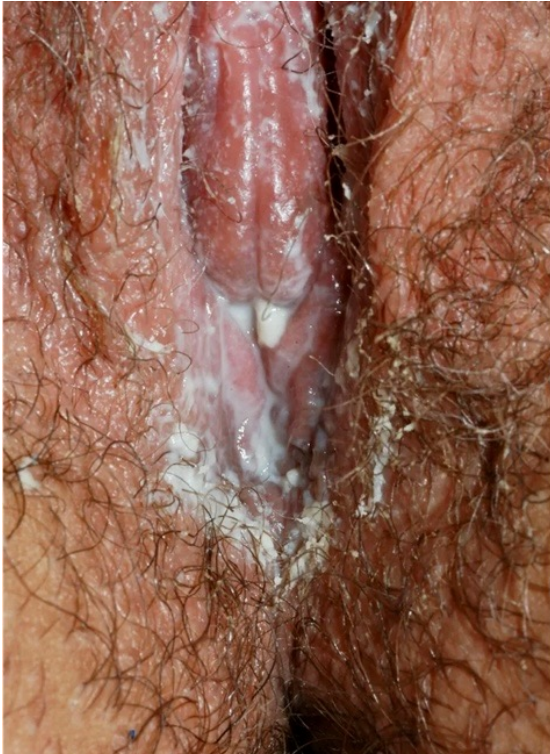**Name the
vulvar
condition
affecting these
two patients**



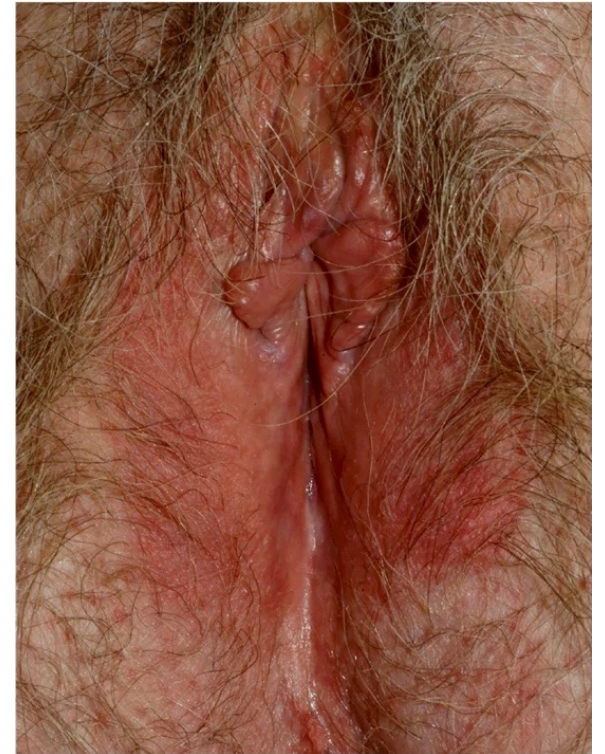
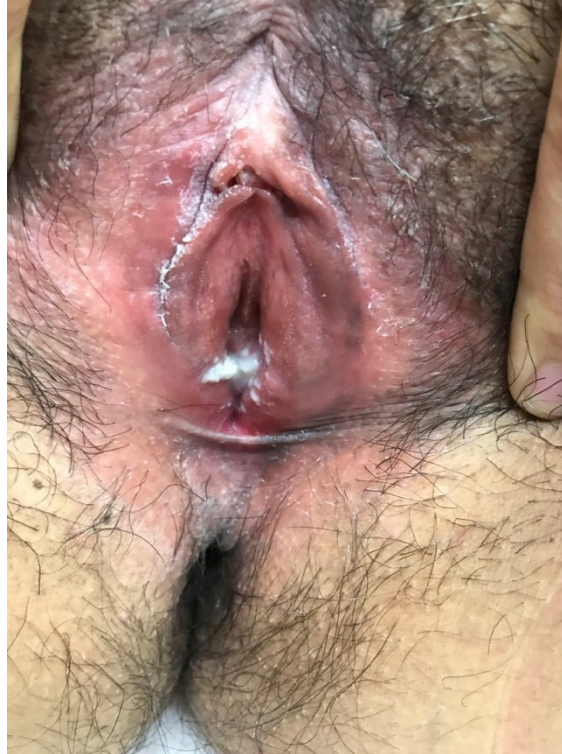- Herpes simplex virus
- Candidiasis
- Squamous cell carcinoma
- Lichen sclerosus

Candidiasis

Candida glabrata



Candida albicans

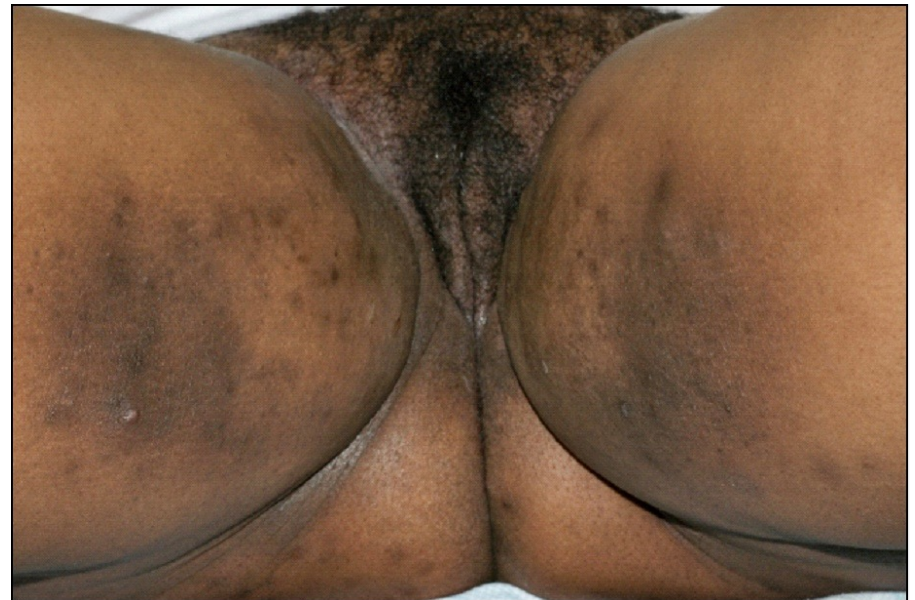

Case #11

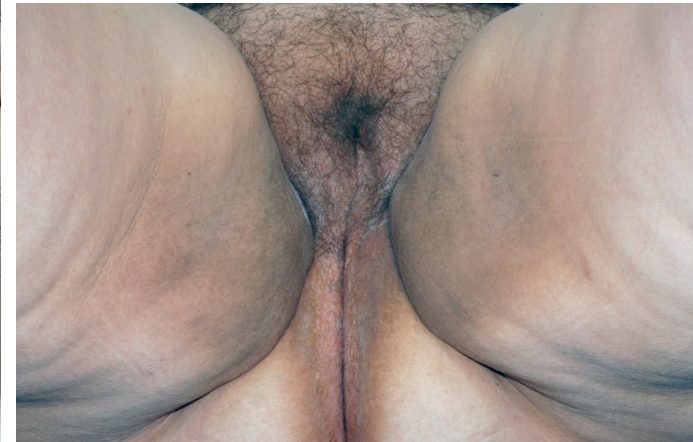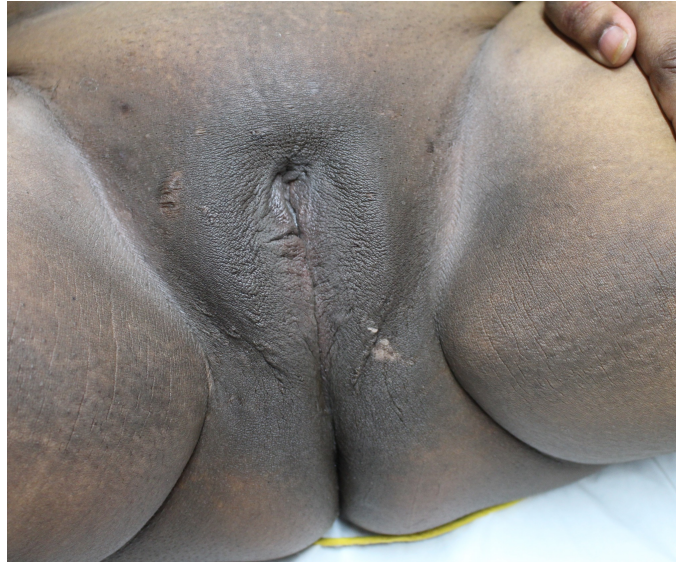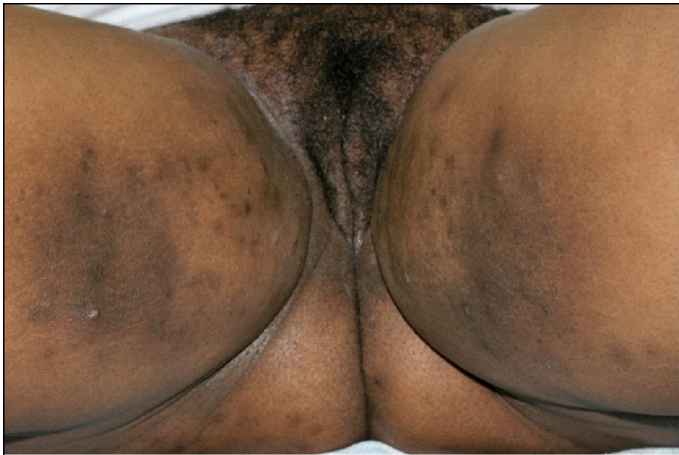29 y.o. female is noted to have dark, velvety patches on her vulva

**Name this
vulvar condition**

- Melanosis
- Eczema
- Lichen simplex chronicus
- Acanthosis nigricans



Acanthosis nigricans

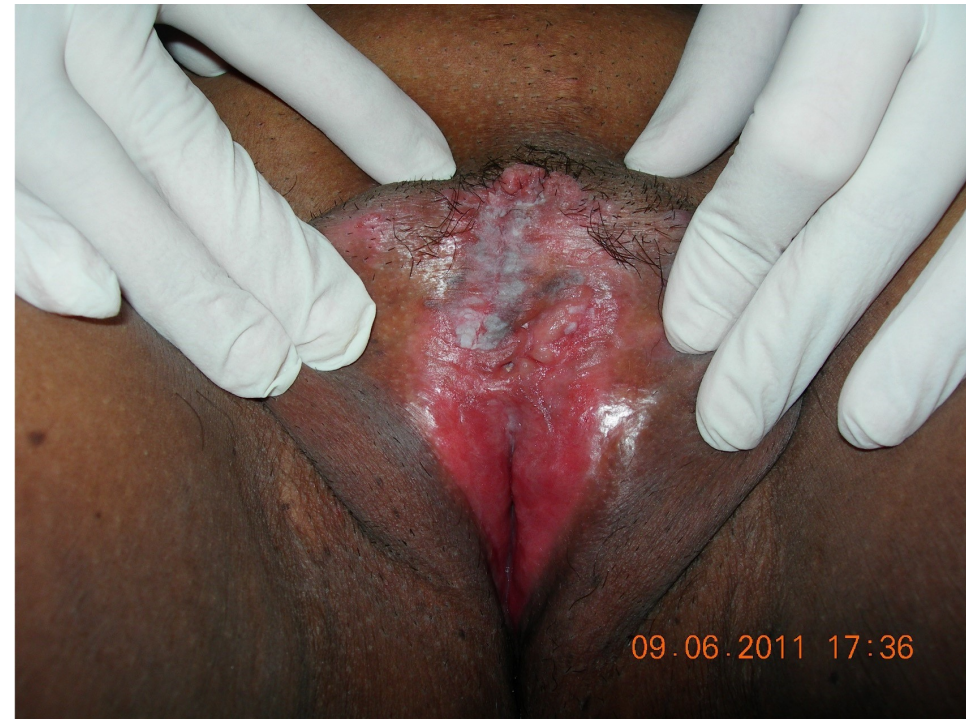

Case #12

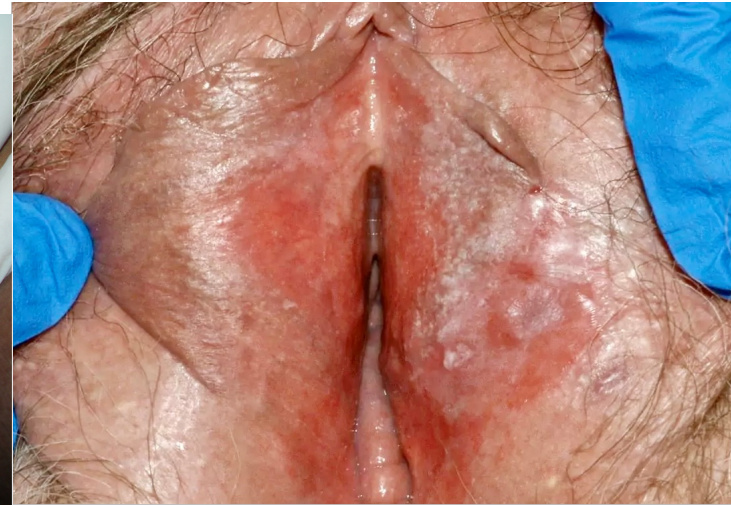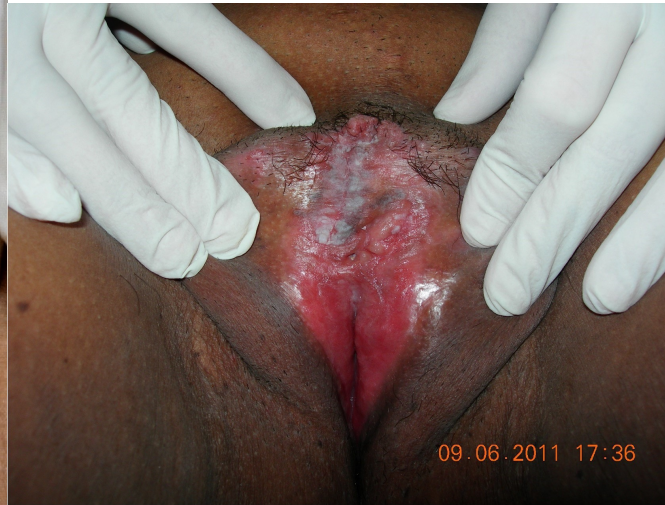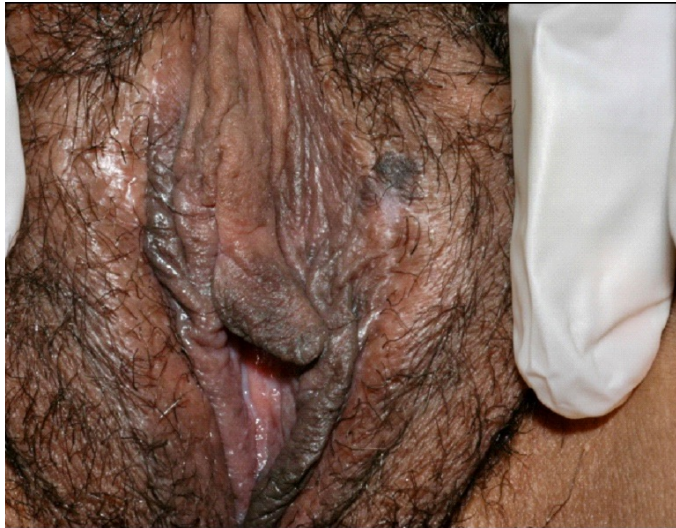53 y.o. female has pruritic vulvar lesions

**Name this
vulvar condition**

- Melanoma
- Actinic keratosis
- High grade squamous intraepithelial lesion (HSIL) of the vulva
- Basal cell carcinoma



HSIL of the vulva (HPV-dependent)

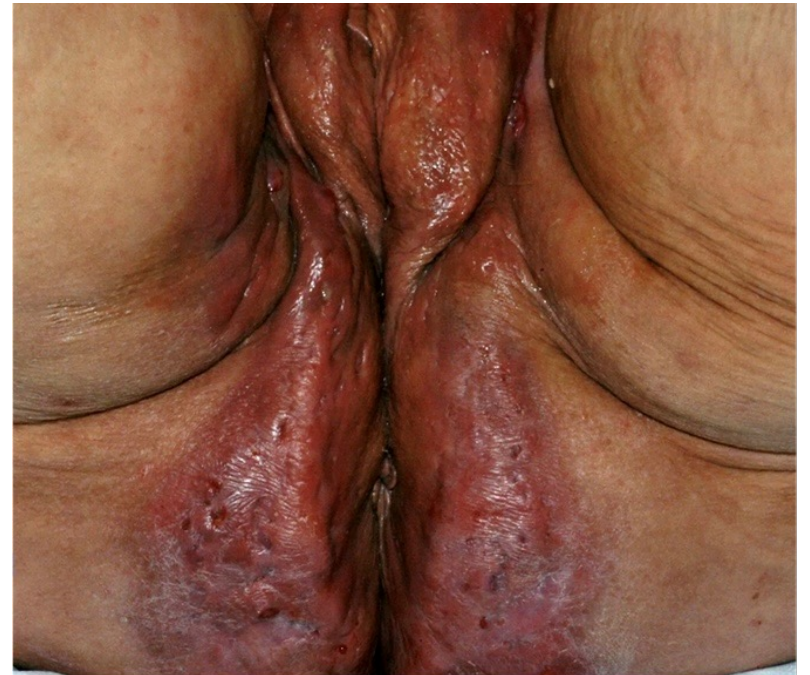

Case #13

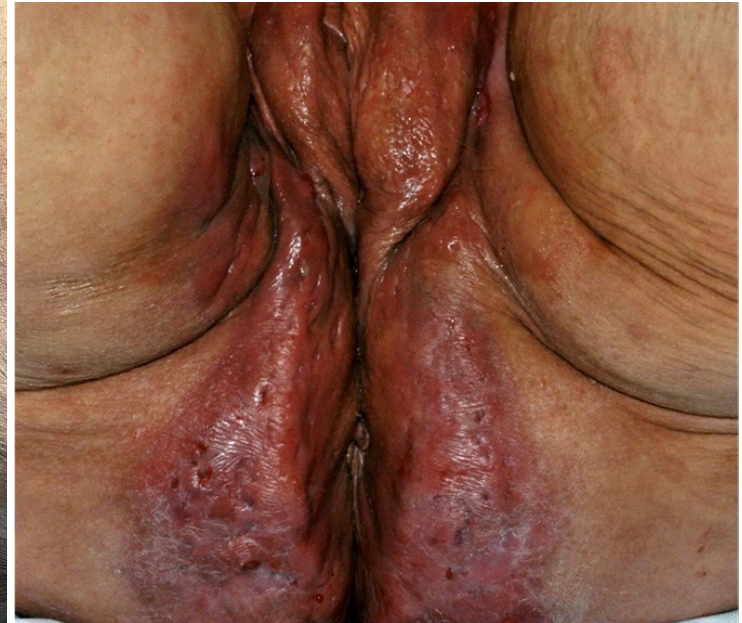
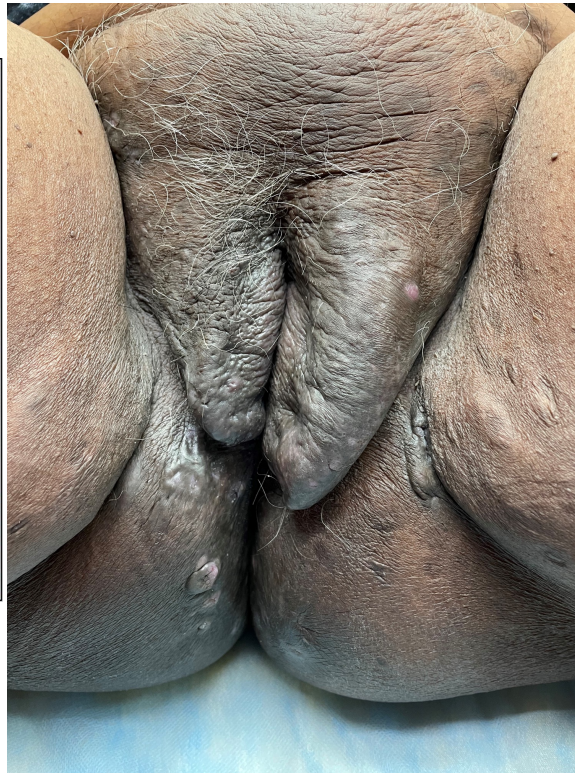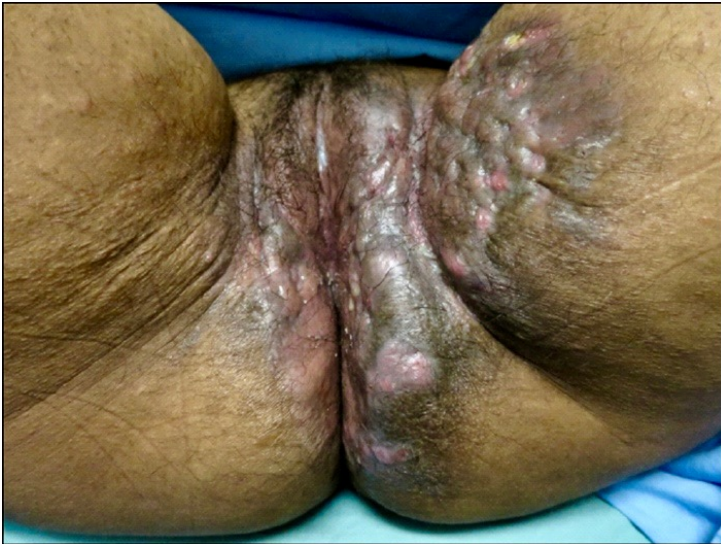35 y.o female complains of painful and recurrent abscesses in her groin

**Name this
vulvar condition**

- Furuncles
- Hidradenitis
suppurativa
- Folliculitis
- Squamous cell
carcinoma



Hidradenitis suppurativa

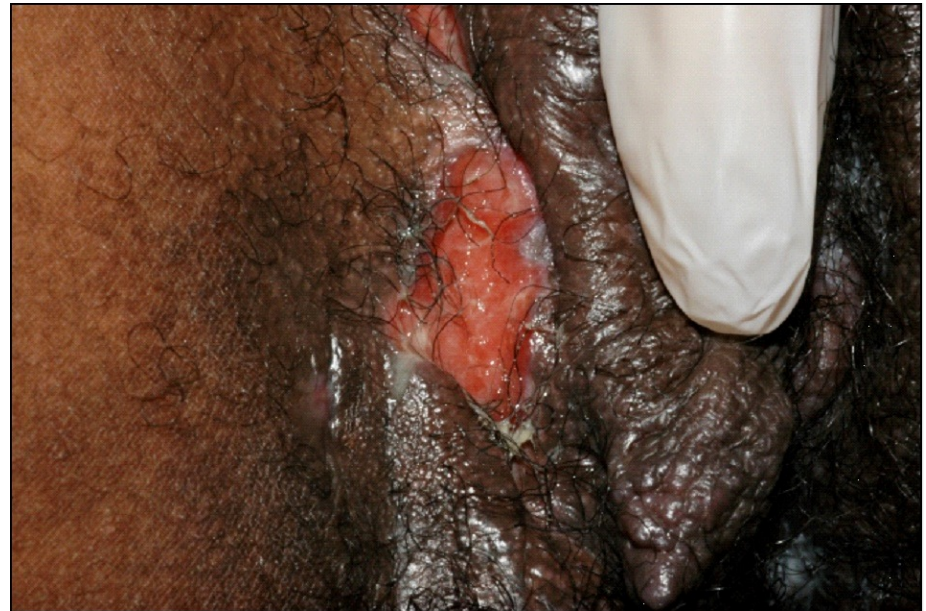

Case #14

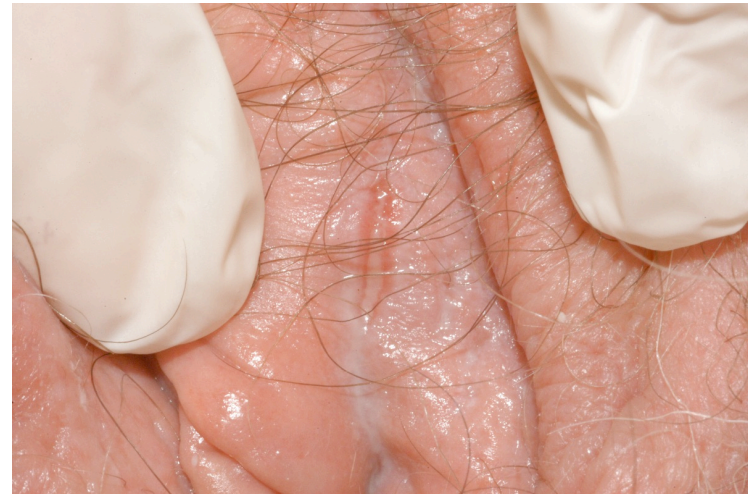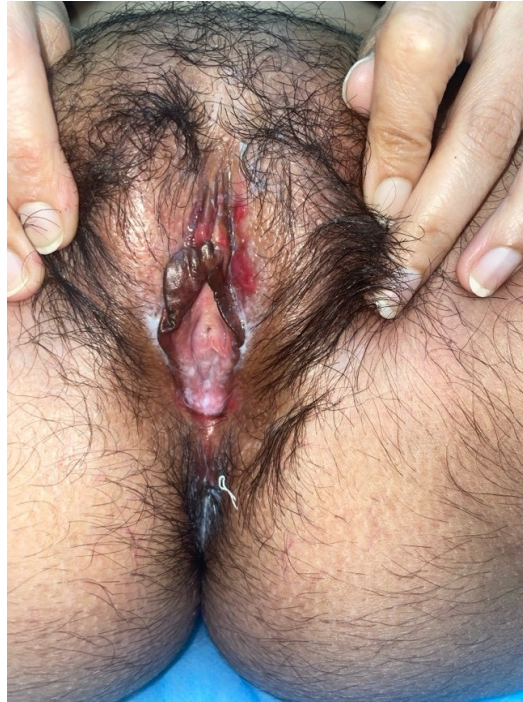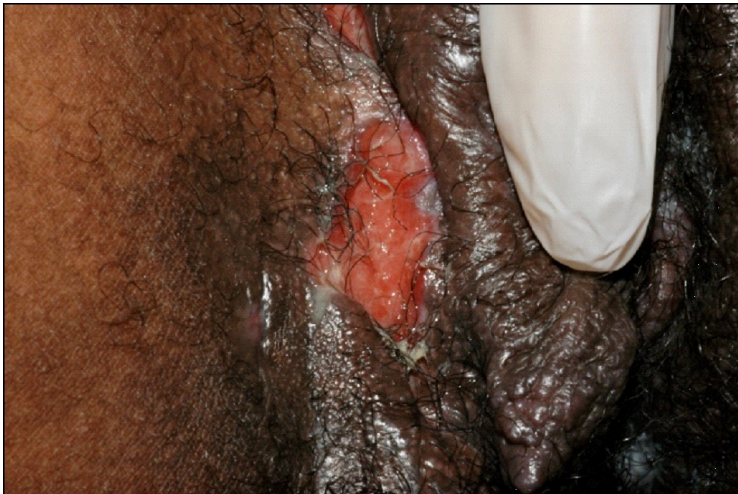40 y.o. female presents with a history of recurrent painful areas on her vulva

**Name this
vulvar condition**

- Lichen sclerosus
- Herpes simplex virus
- Behcet's disease
- Crohn's disease



Crohn's disease of the vulva

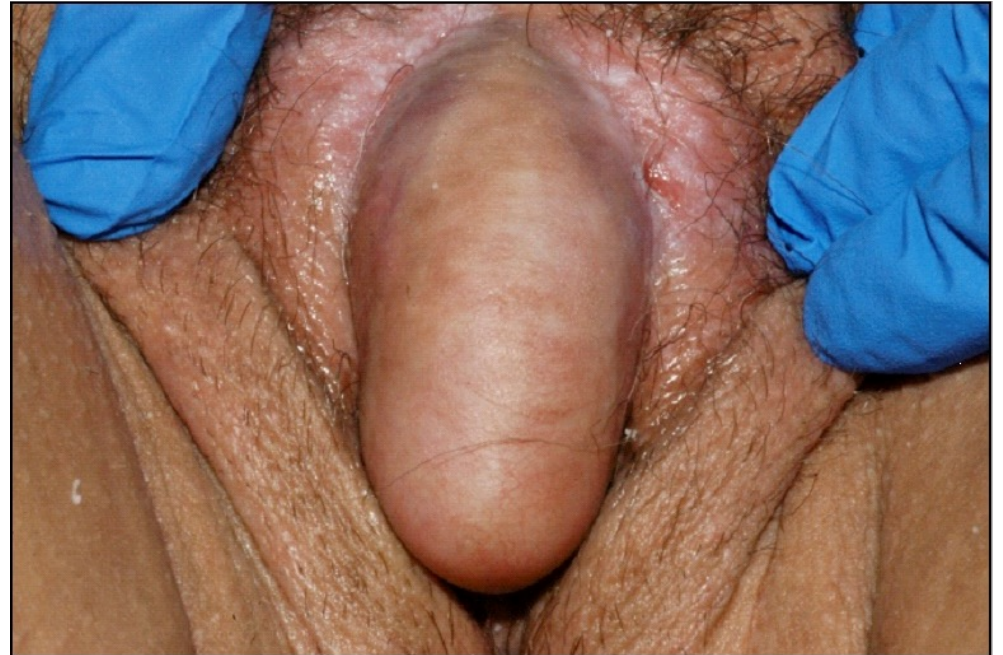


Case #15

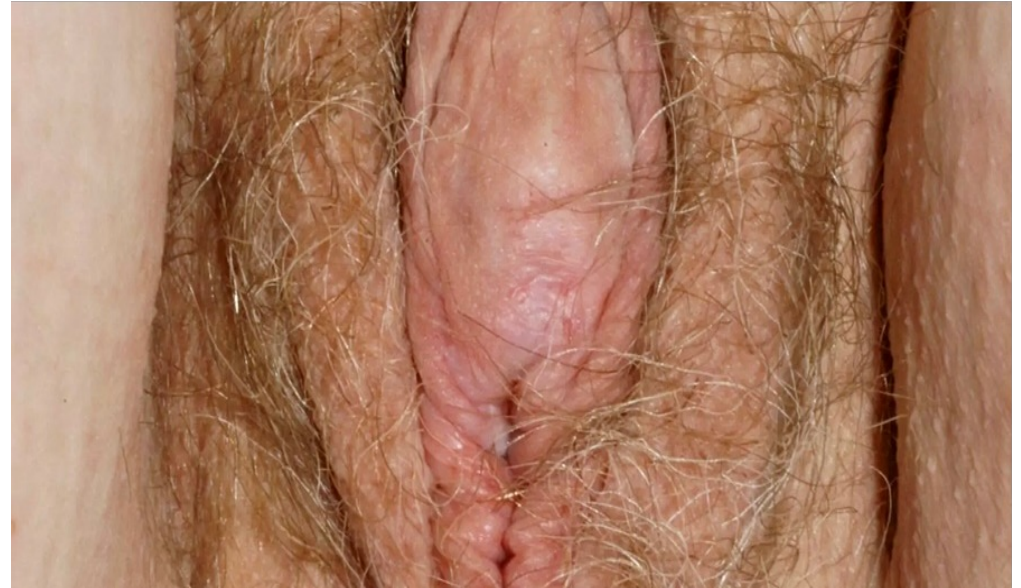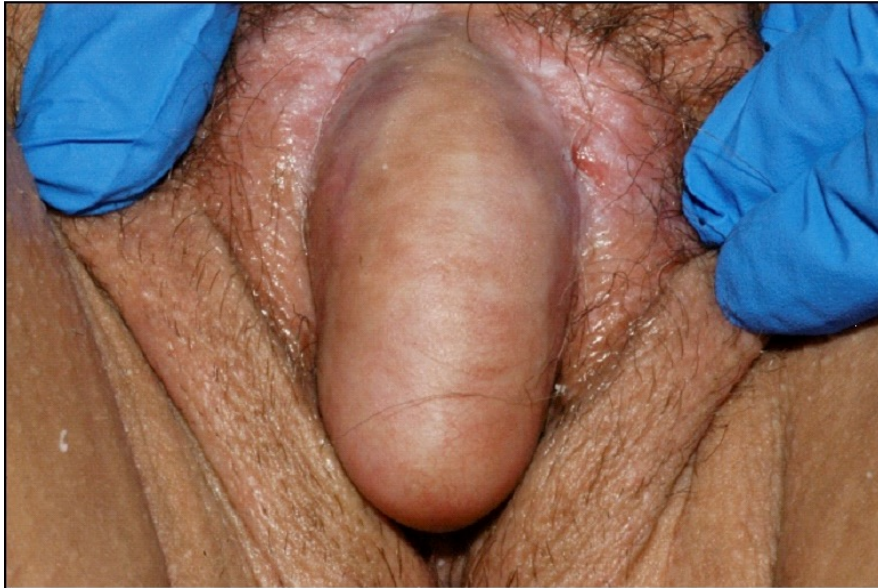41 y.o. female notes a painless lump on her vulva

**Name this
vulvar condition**

- Papilloma
- Clitoromegaly
- Prepuce cyst
- Hemangioma



Prepuce cyst

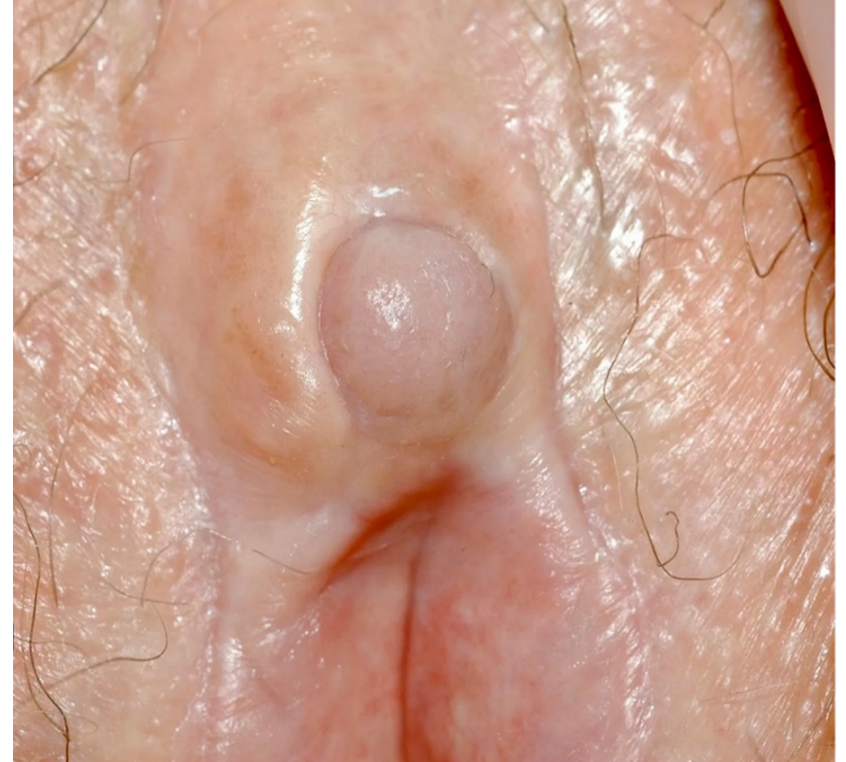

Case #16

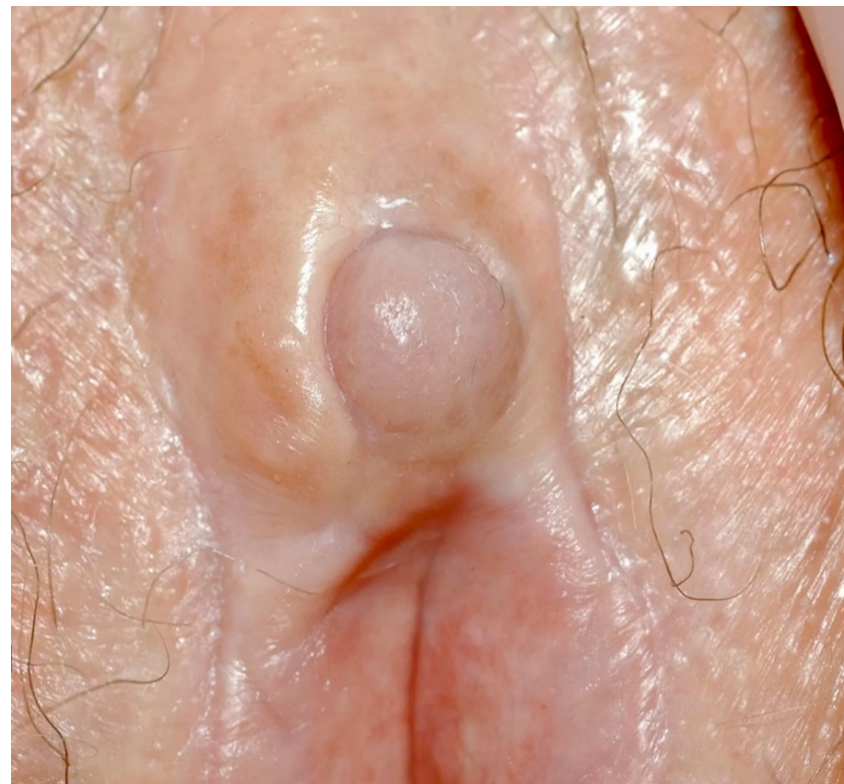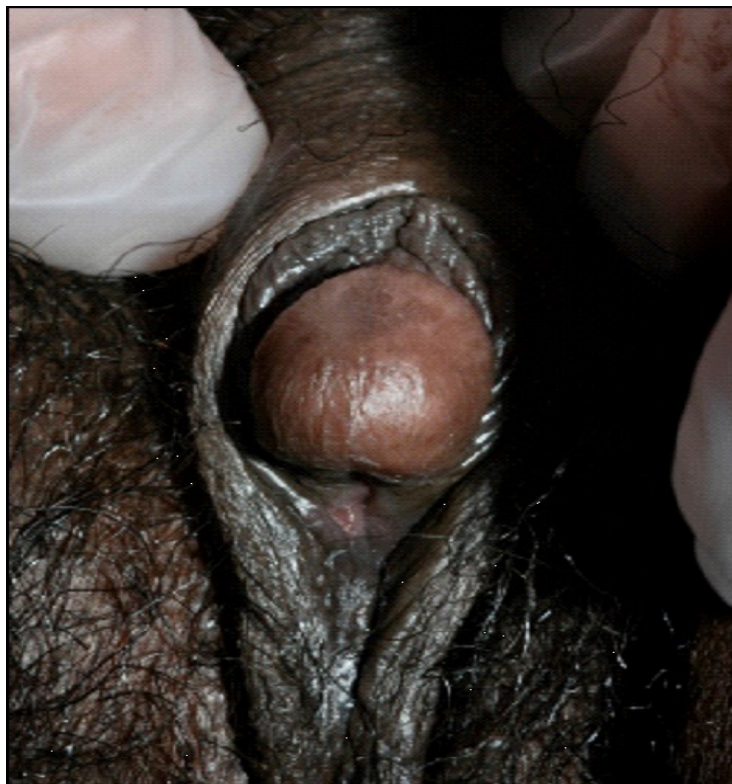
33 y.o. female recently increased their testosterone dose and now notices clitoral enlargement

**Name this
vulvar condition**

- Hematoma
- Sebaceous cyst
- Lipoma
- Clitoromegaly



Clitoromegaly

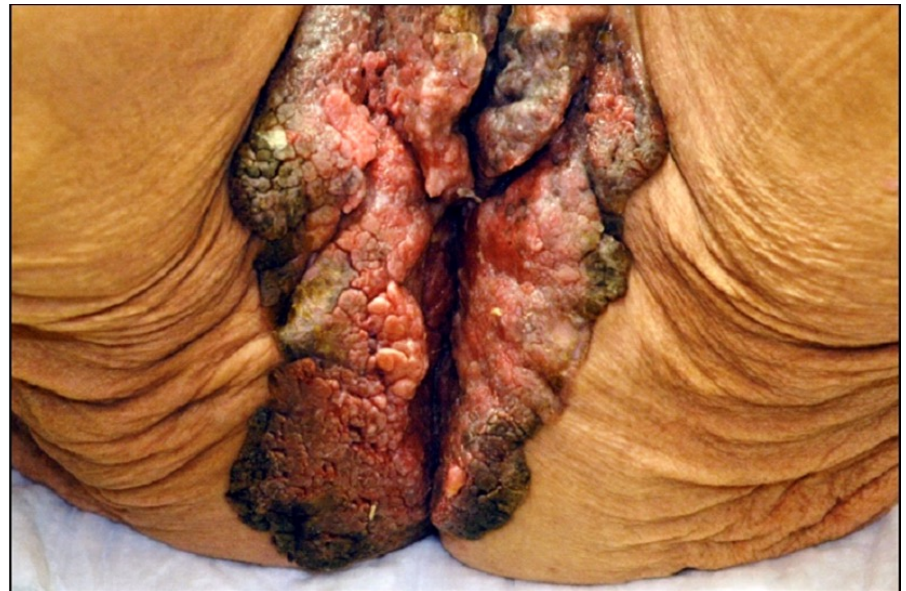

Case #17

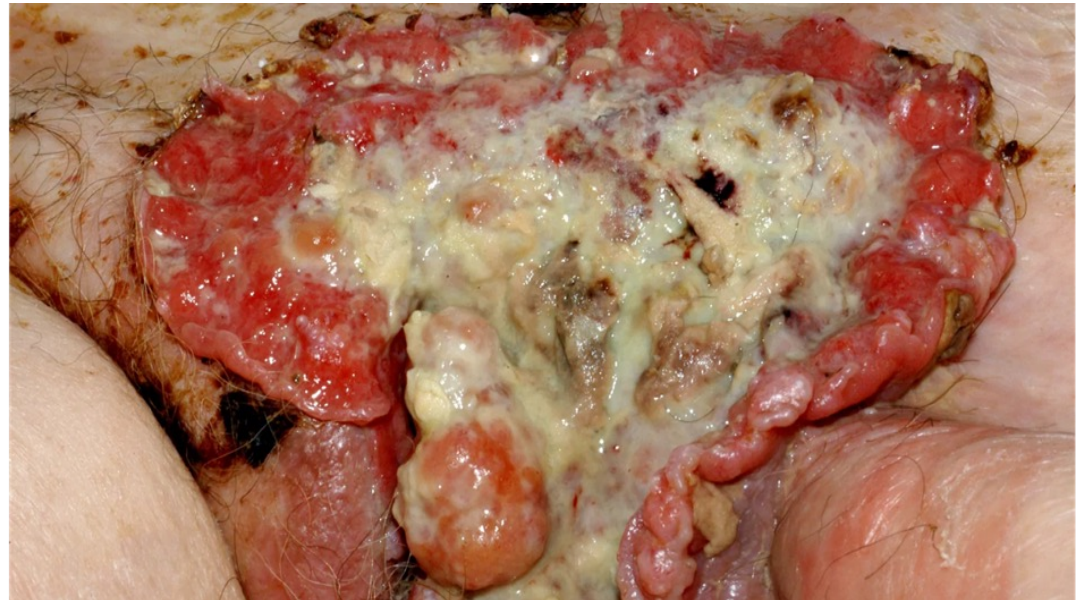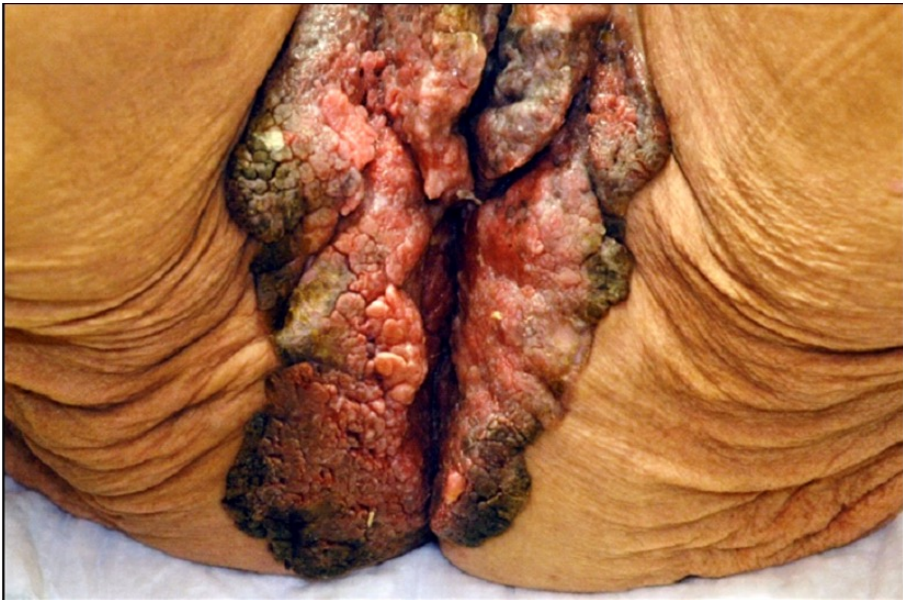54 y.o. female complains of persistent vulvar lesions and bleeding

**Name this
vulvar condition**

- Hidradenitis suppurativa,
- Invasive squamous cell carcinoma
- Lichen planus,
- Pyogenic granuloma



Invasive squamous cell carcinoma

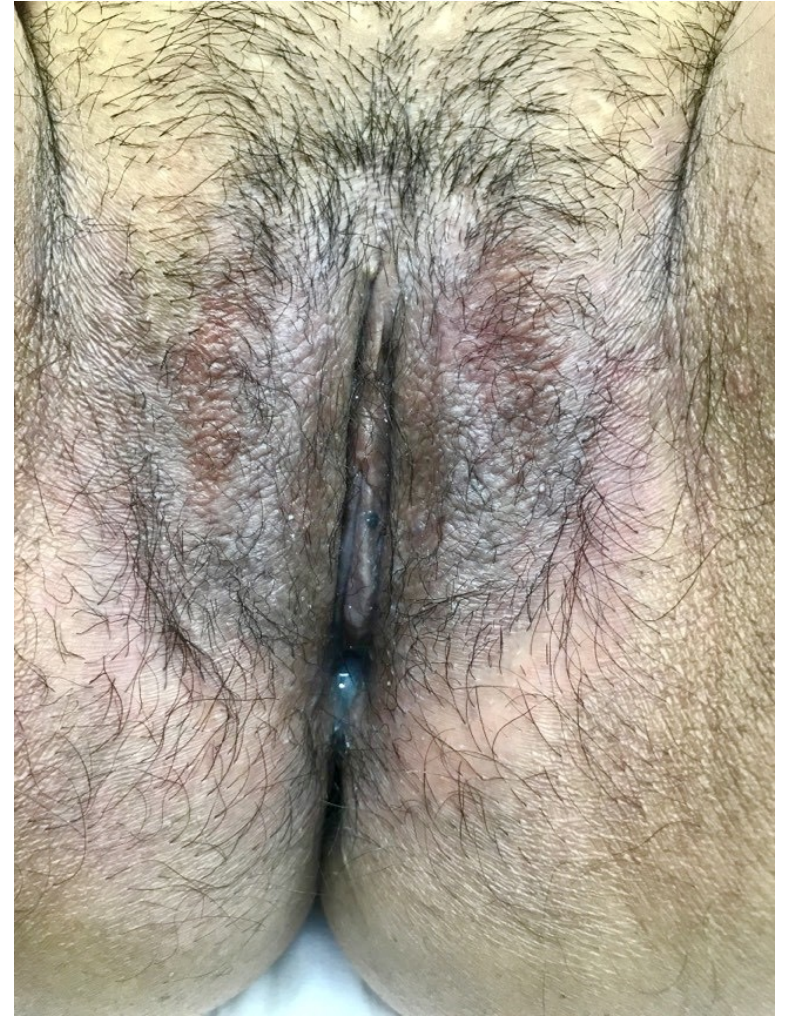


Case #18

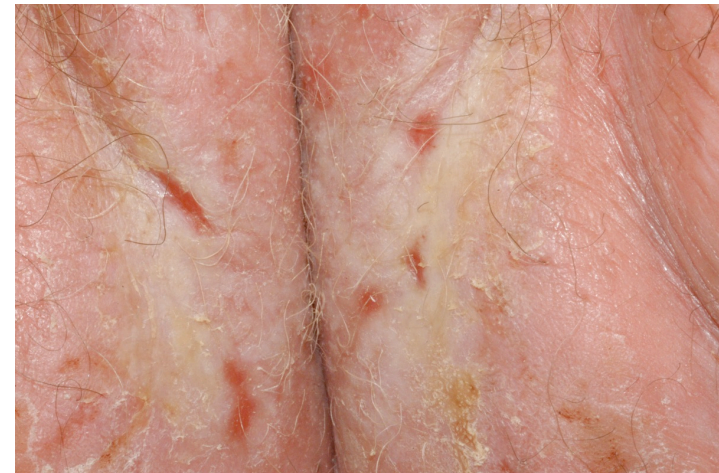
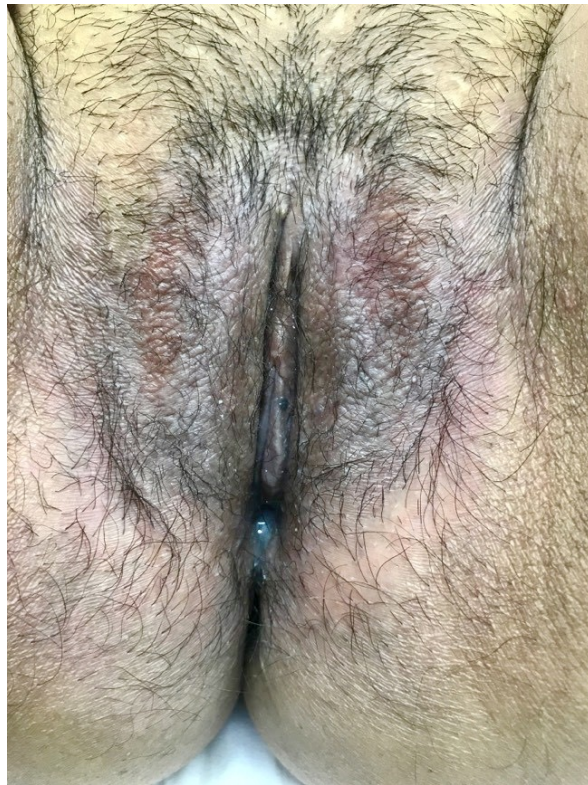
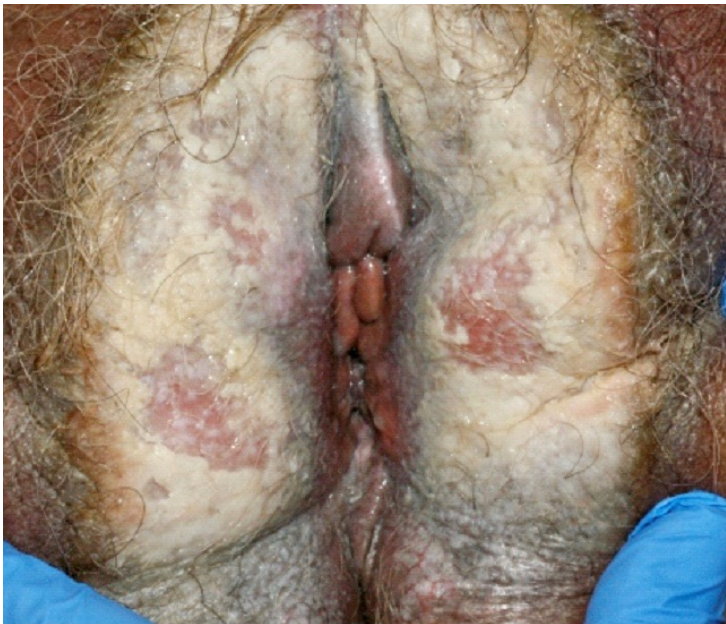45 y.o. female has intense vulvar pruritus. It awakens her at night. A yeast culture was negative. She has been intermittently treated without success with Class I topical steroids for over a year.

**Name this
vulvar condition**

- Psoriasis
- Lichen planus
- Eczema
- Lichen simplex chronicus



Lichen simplex chronicus

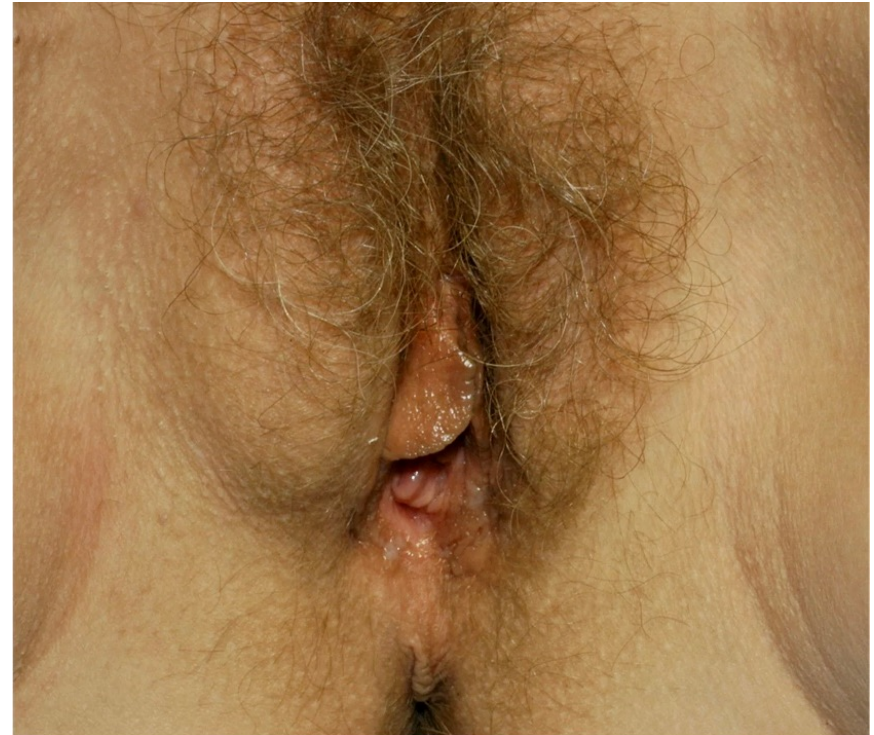

Case #19

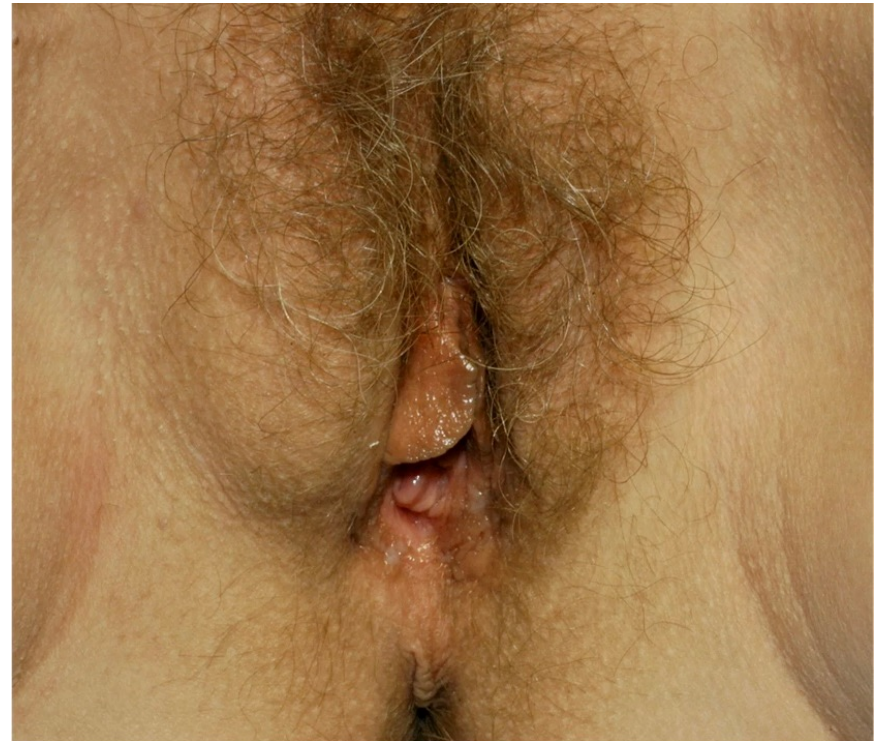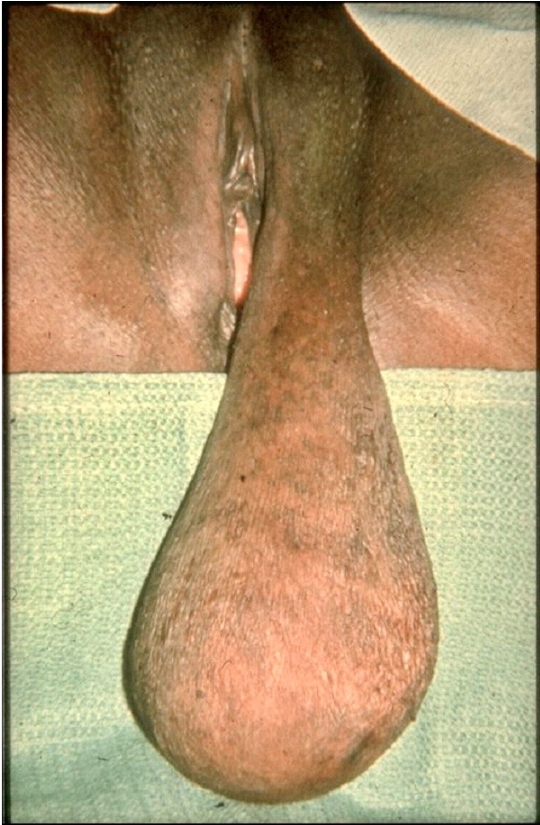46 y.o. female notes a soft, painless lump on her vulva

**Name this
vulvar condition**

- Hemangioma
- Epiderma inclusion cyst
- Lipoma
- Fibroma



Lipoma

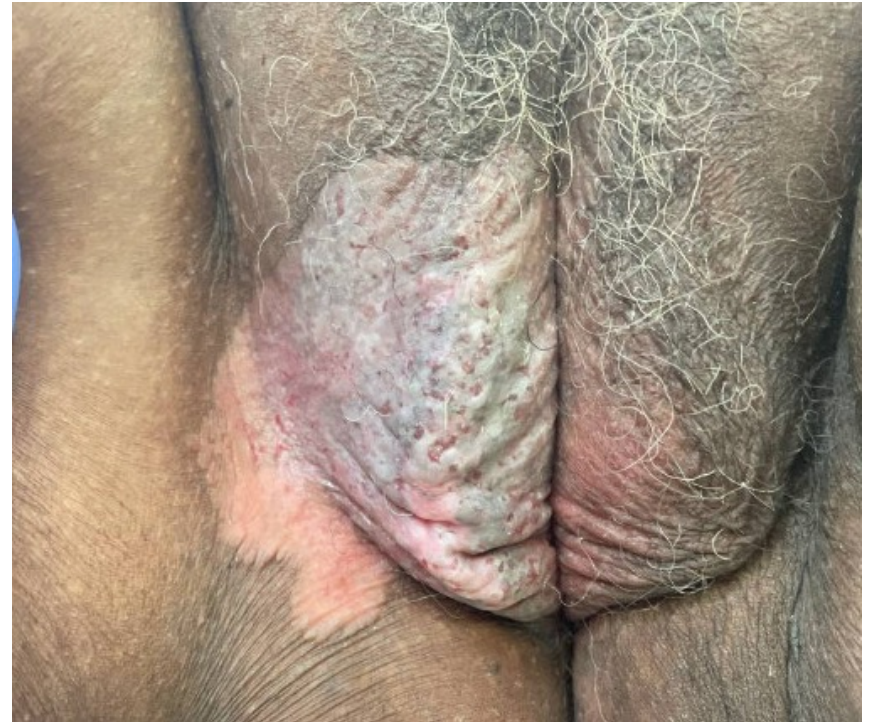

Case #20

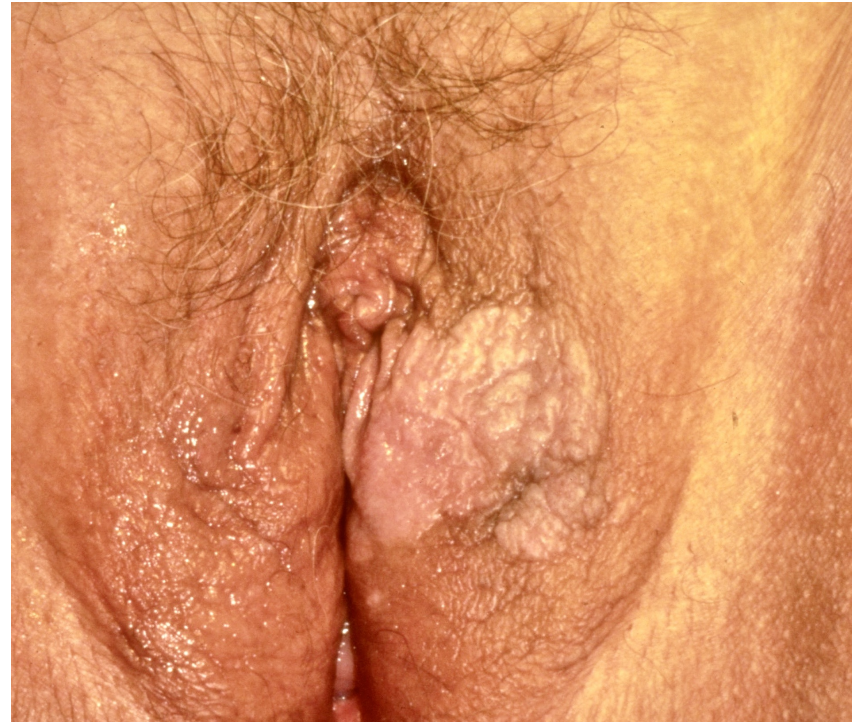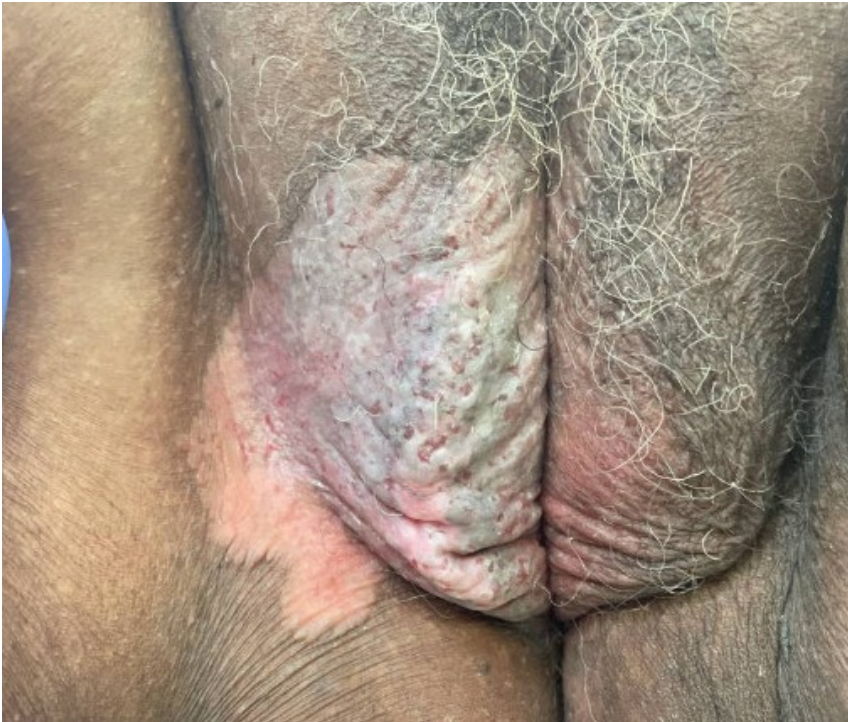65 y.o. female presents with a chronic, itchy, and erythematous vulvar lesion with a distinct, well-defined margin, not relieved with OTC yeast medications or fluconazole

**Name this
vulvar condition**

- Resistant candidiasis
- Lichen Planus
- Extramammary Paget's
- Vulvodynia



Extra-mammary Paget's disease



Key of Vulvovaginal Diseases

1. LSIL of the vulva (condyloma acuminatum)
2. Lichen sclerosus
3. Aphthous ulcers
4. Epidermal inclusion cyst
5. Lichen planus
6. Varicosities
7. Melanosis
8. Bartholin's cyst
9. Herpes simplex virus
10. Candidiasis
11. Acanthosis nigricans
12. HSIL of the vulva
13. Hidradenitis suppurativa
14. Crohn's disease
15. Prepuce cyst
16. Clitoromegaly
17. Invasive squamous cell carcinoma
18. Lichen simplex chronicus
19. Lipoma
20. Extra-mammary Paget's disease